

Fracture Neck Femur

An anatomical model of a human femur (thigh bone) is shown with a clear fracture at the neck. The bone is positioned vertically, with the head at the top and the shaft extending downwards. The fracture line is visible at the junction of the head and neck. The background is a semi-transparent image of a human torso, showing the ribcage and spine, which is overlaid on a dark blue gradient.

Dr. Ashish Gohiya

MS (Orth), FIAS, FIOS (UK)

Professor & Head

Department of Orthopaedics

Gandhi Medical College, Bhopal

OR 2.10

Describe and discuss the aetiopathogenesis, mechanism of injury, clinical features, investigations and principles of management of fractures of proximal femur - #Neck of femur and Intertrochanteric femur

OR 2.10

प्रॉक्सिमल फीमर (proximal femur) [फीमर नेक (*neck of femur*) और इंटरट्रोकेण्टरिक फीमर (*intertrochanteric femur*)] फ्रैक्चर की एटियोपैथोजेनेसिस, चोट की प्रक्रिया, नैदानिक लक्षण, जांच और उपचार के सिद्धांतों का वर्णन और चर्चा करें।"

OR 2.10

1. Aetiopathogenesis
2. Mechanism of injury
3. Clinical features
4. Investigations
5. Principles of management

#Neck of femur and
Intertrochanteric femur

OR 2.10

1. एटियोपैथोजेनेसिस
2. चोट की प्रक्रिया
3. नैदानिक लक्षण
4. जांच
5. उपचार के सिद्धांत

फीमर नेक और इंटरट्रोकेण्टरिक फीमर
फ्रैक्चर

DISCLAIMER

There will be a test at the end

Attendance will be based on test marks

एनाटॉमी

Articular surface - :Lunate surface

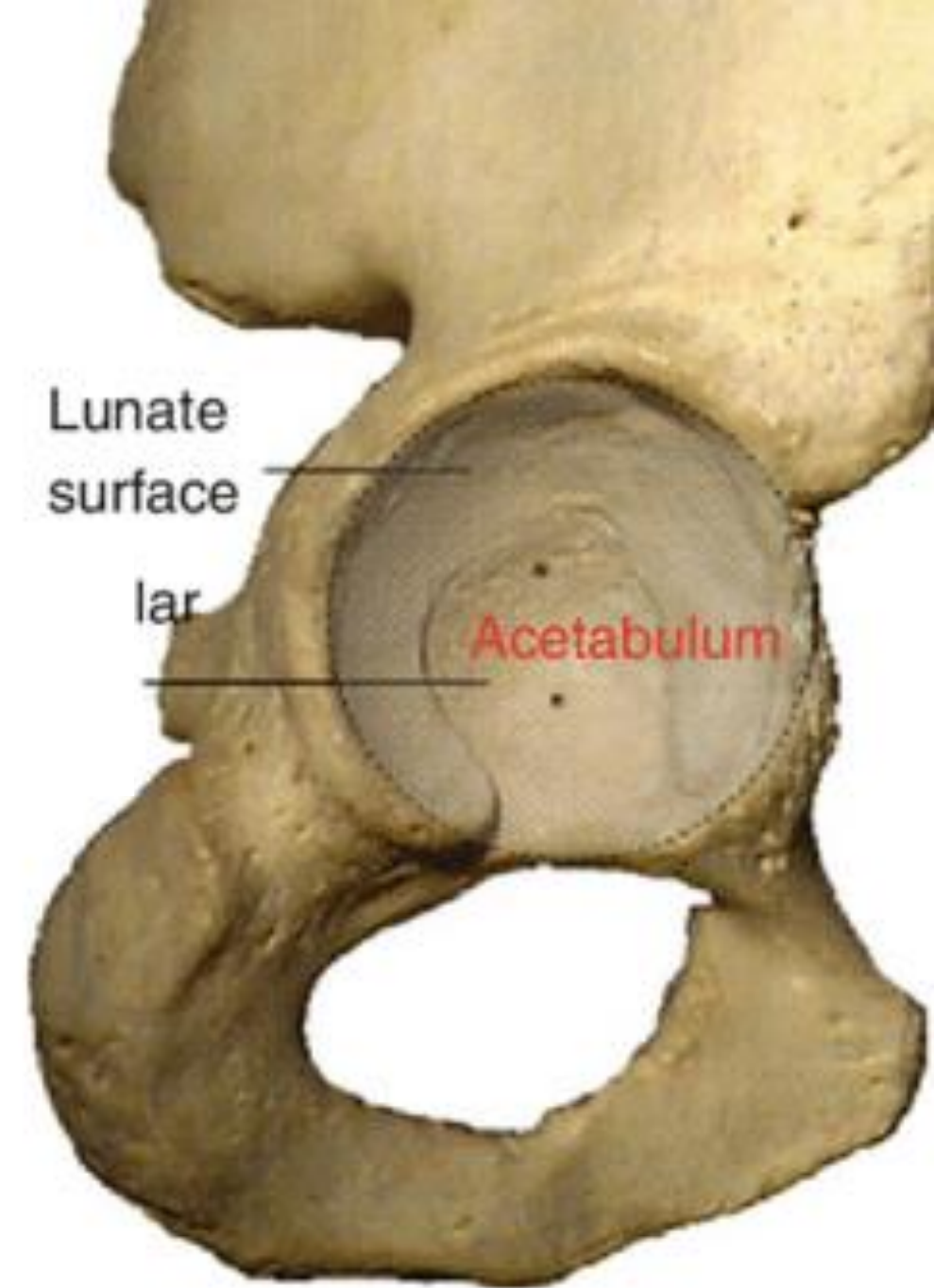
आर्टिक्युलर सर्फेस : ल्यूनेट सर्फेस

Acetabular Fossa

ऐसिटैब्युलर फोसा

Ligamentum Teres

लिगामेंटम टीरेस



Articular surface - :Lunate surface

आर्टिक्युलर सर्फेस : ल्यूनेट सर्फेस

Acetabular Fossa

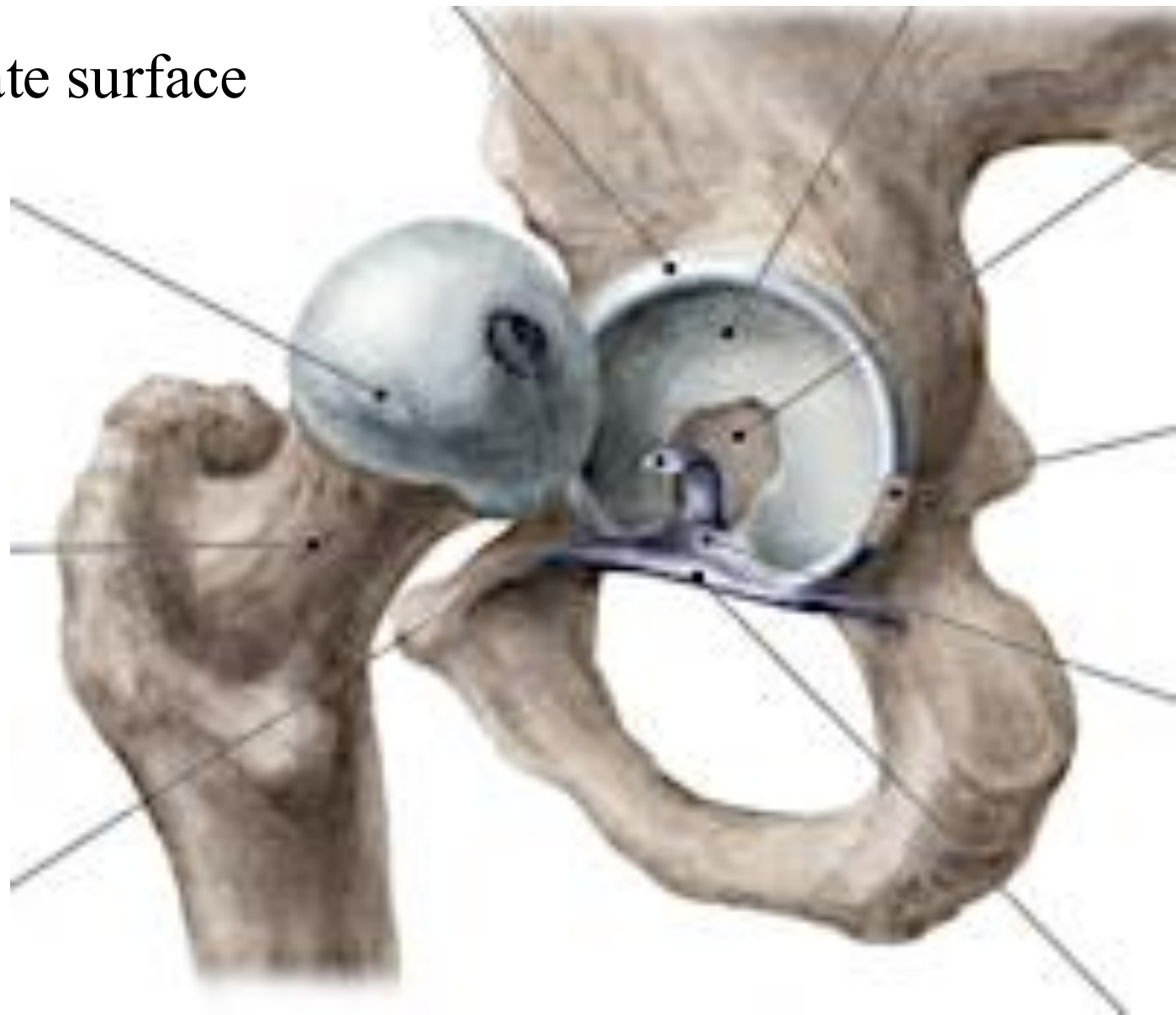
ऐसिटैब्युलर फोसा

Ligamentum Teres

लिगामेंटम टीरेस

Acetabular Labrum

ऐसिटैबुलम लैब्रम



Articular surface - :Lunate surface

आर्टिक्युलर सर्फेस : ल्यूनेट सर्फेस

Acetabular Fossa

ऐसिटैब्युलर फोसा

Ligamentum Teres

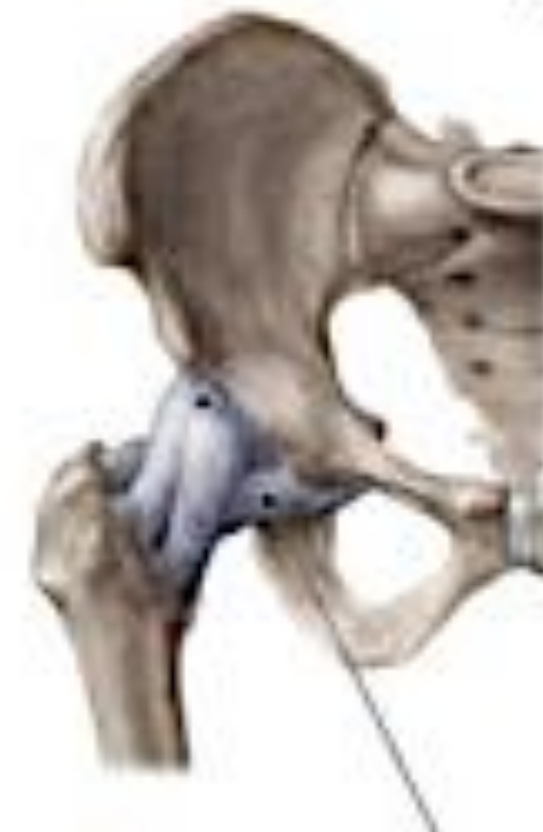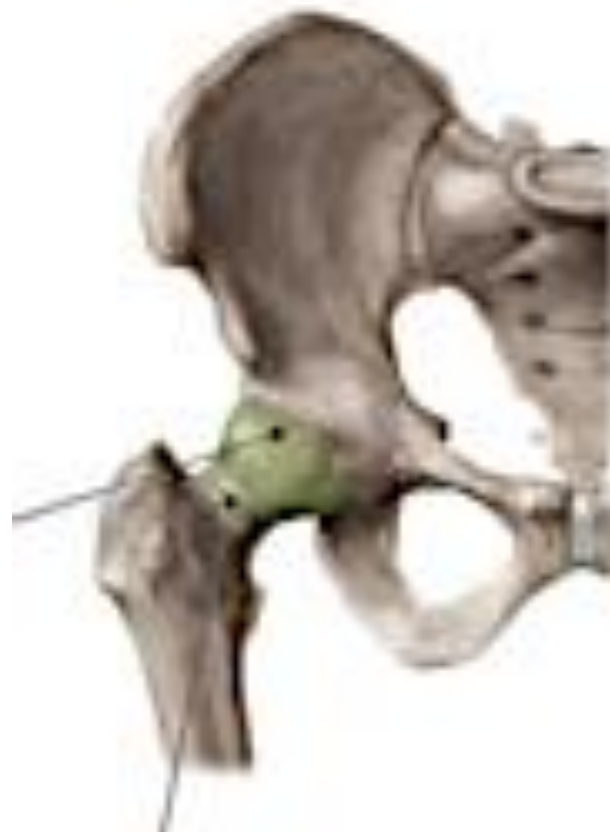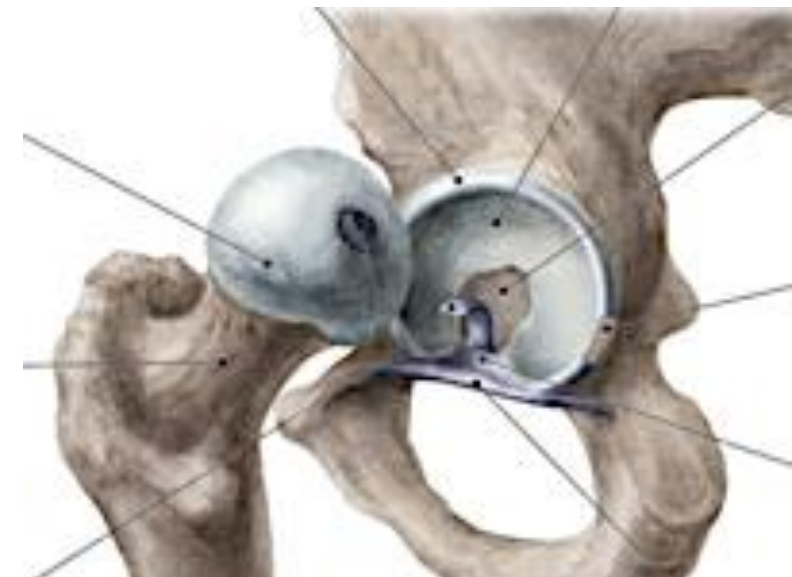लिगामेंटम टीरेस

Acetabular Labrum

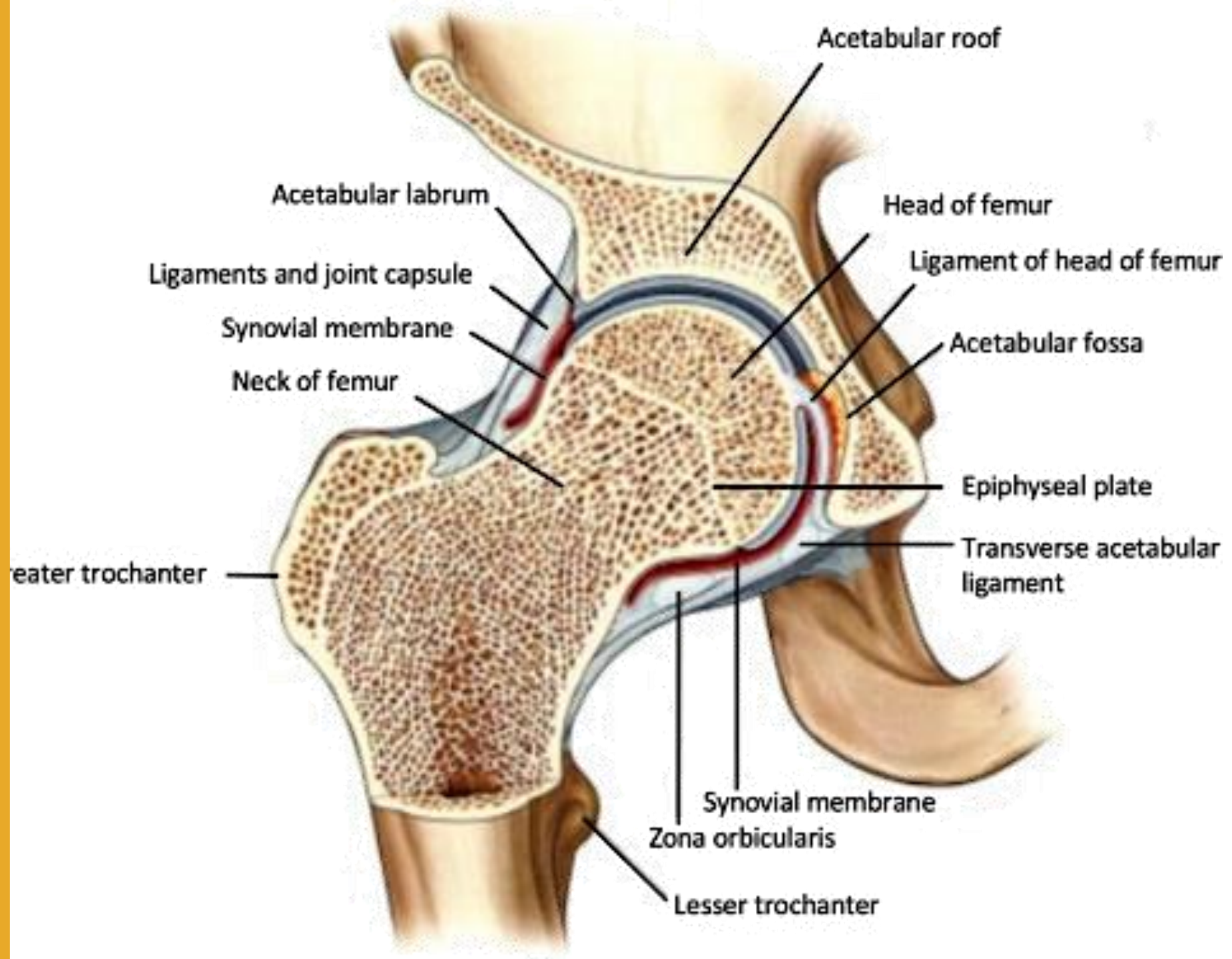
ऐसिटैबुलम लैब्रम

Hip Joint Capsule

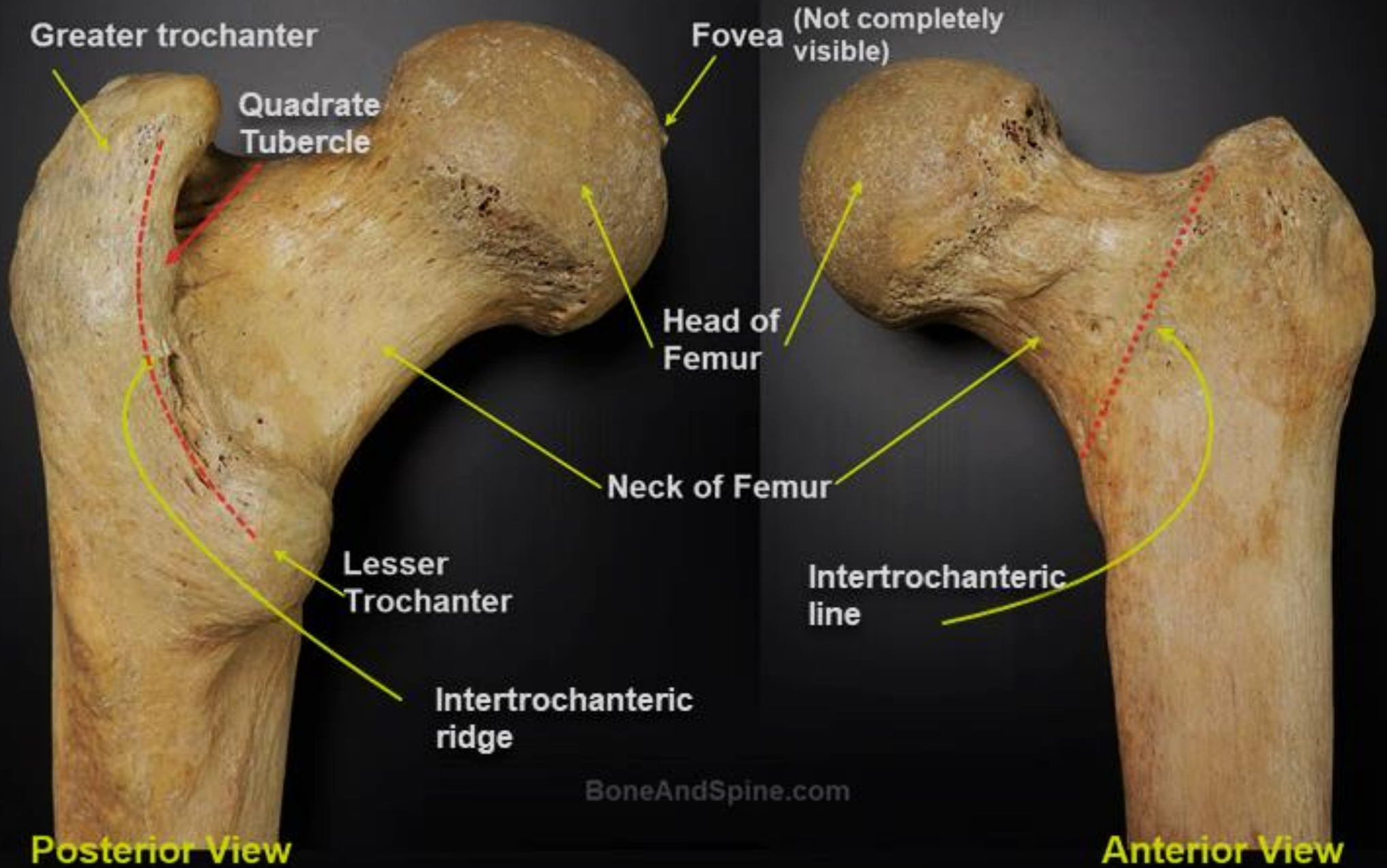
हिप जॉइंट कैप्सूल



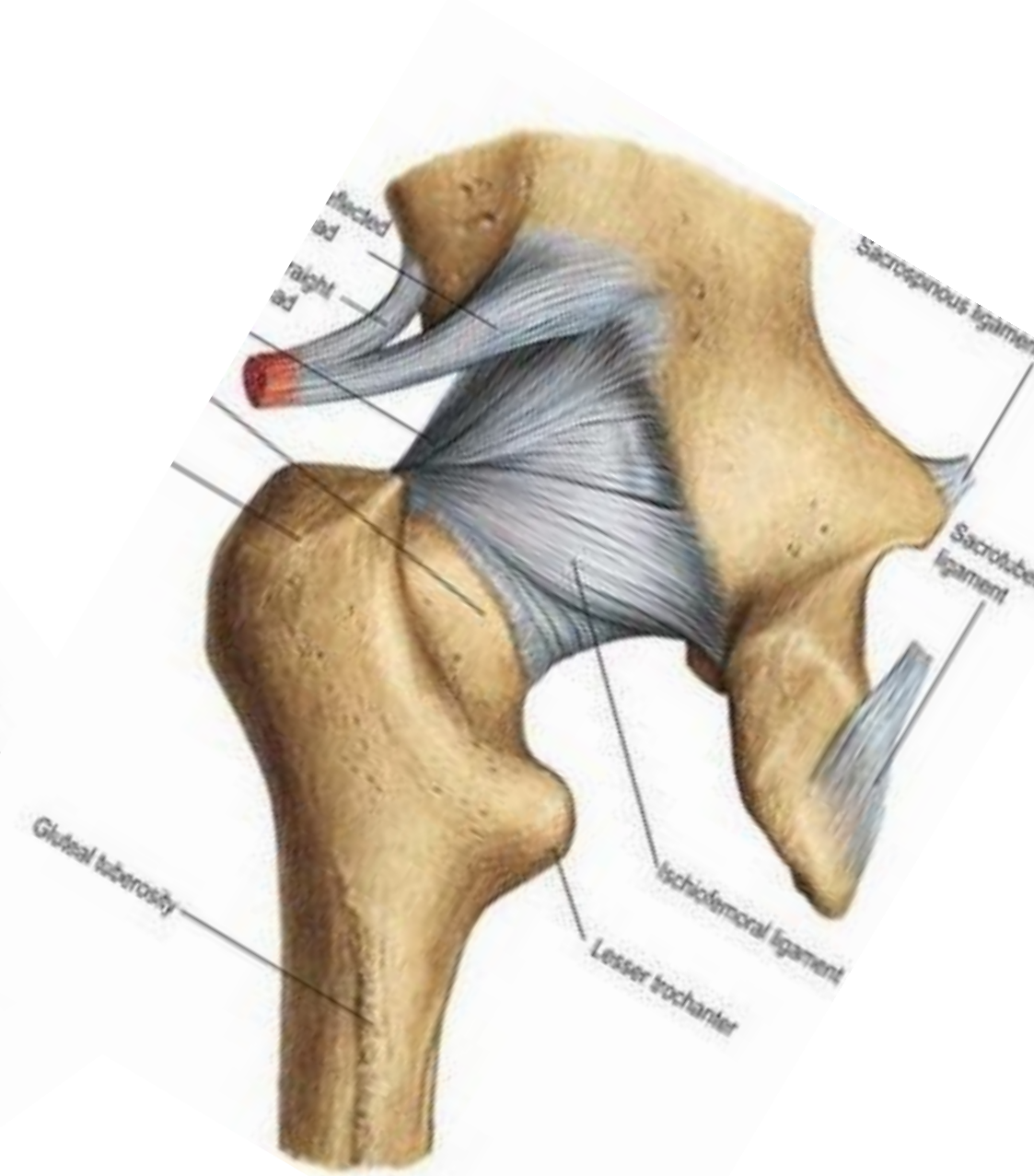
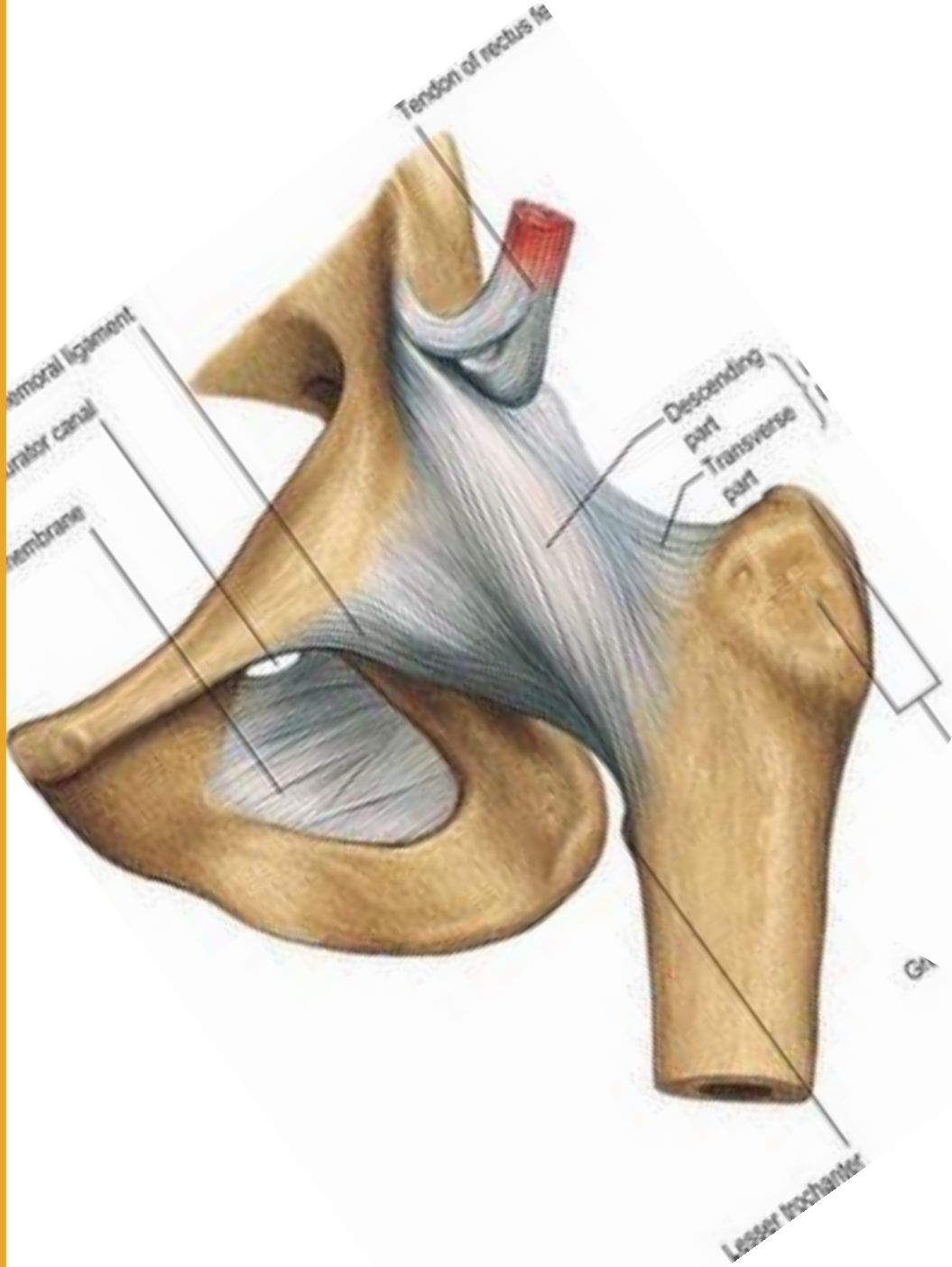
प्रतिभा



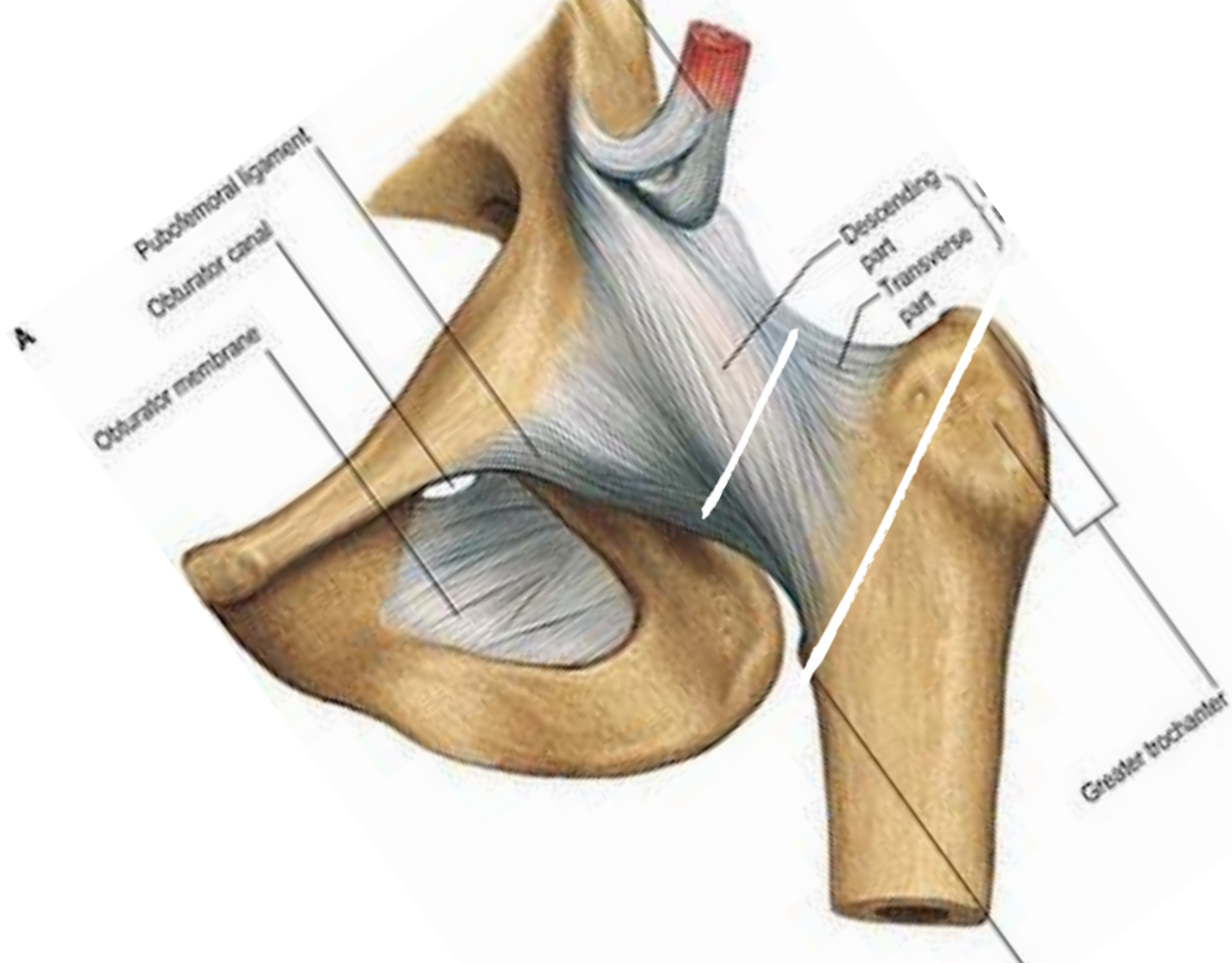
एनाटॉमी

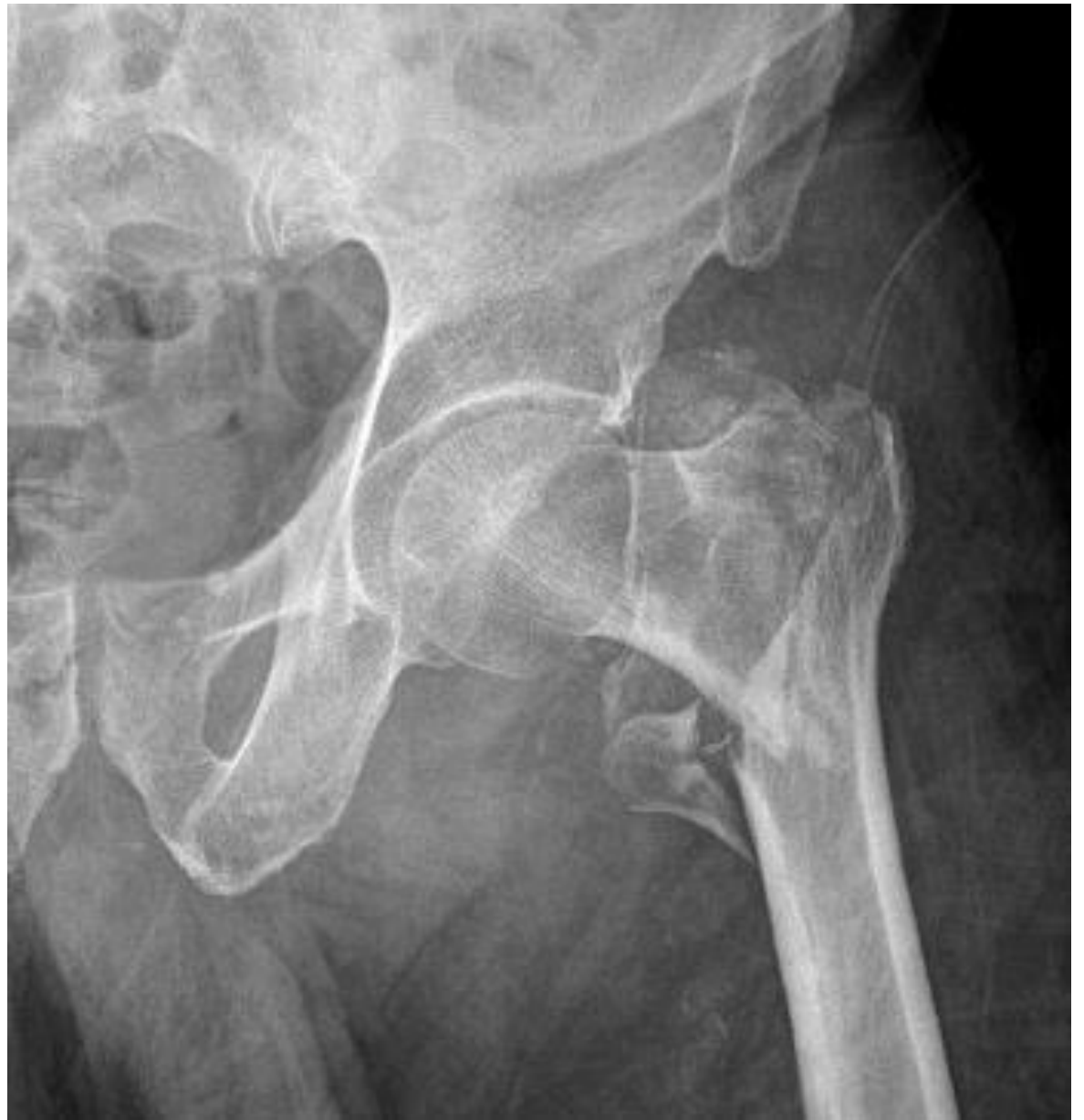
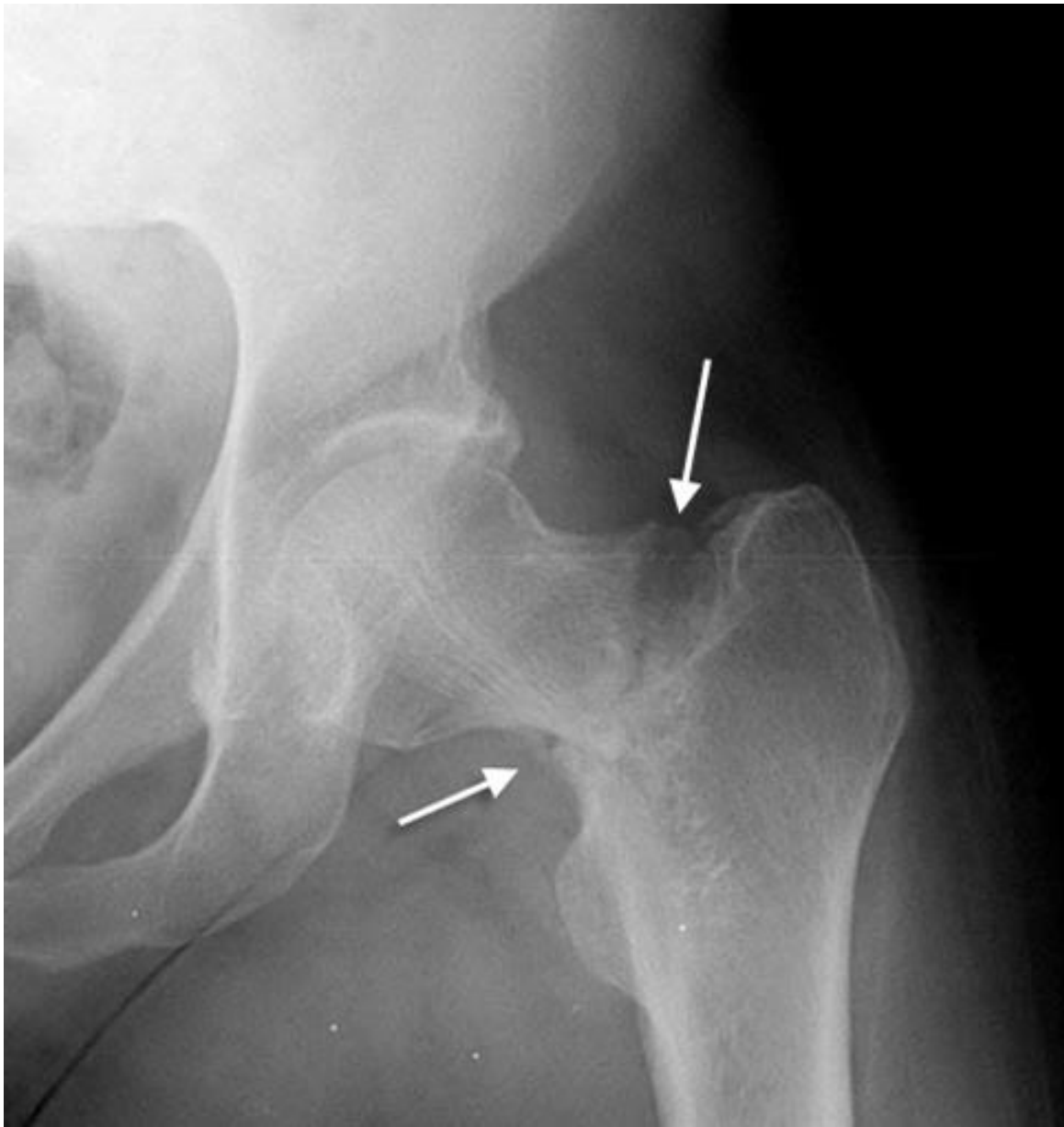
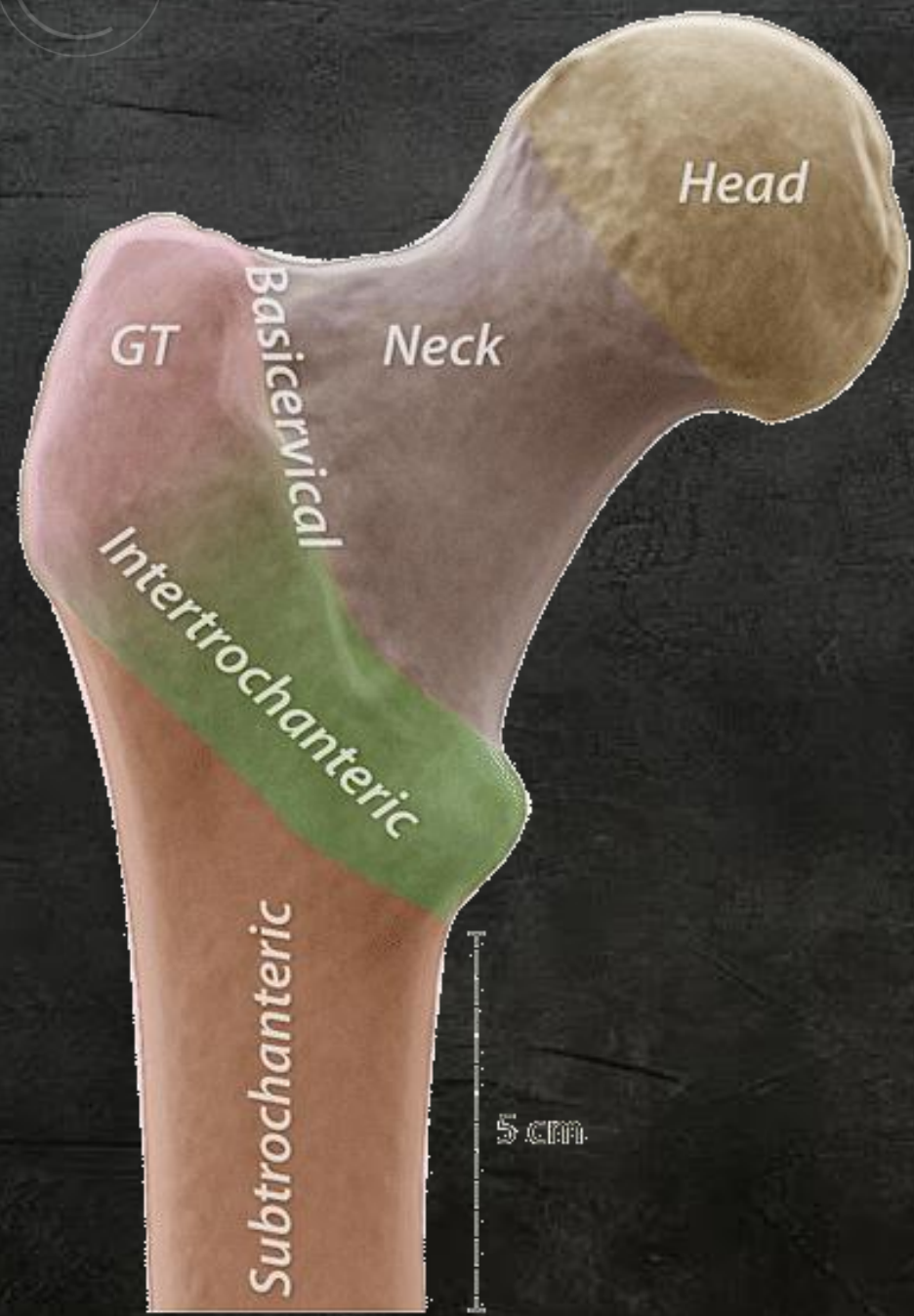
एनाटॉमी



इंट्रा कैप्सुलर / एक्सट्रा कैप्सुलर







Head

Neck

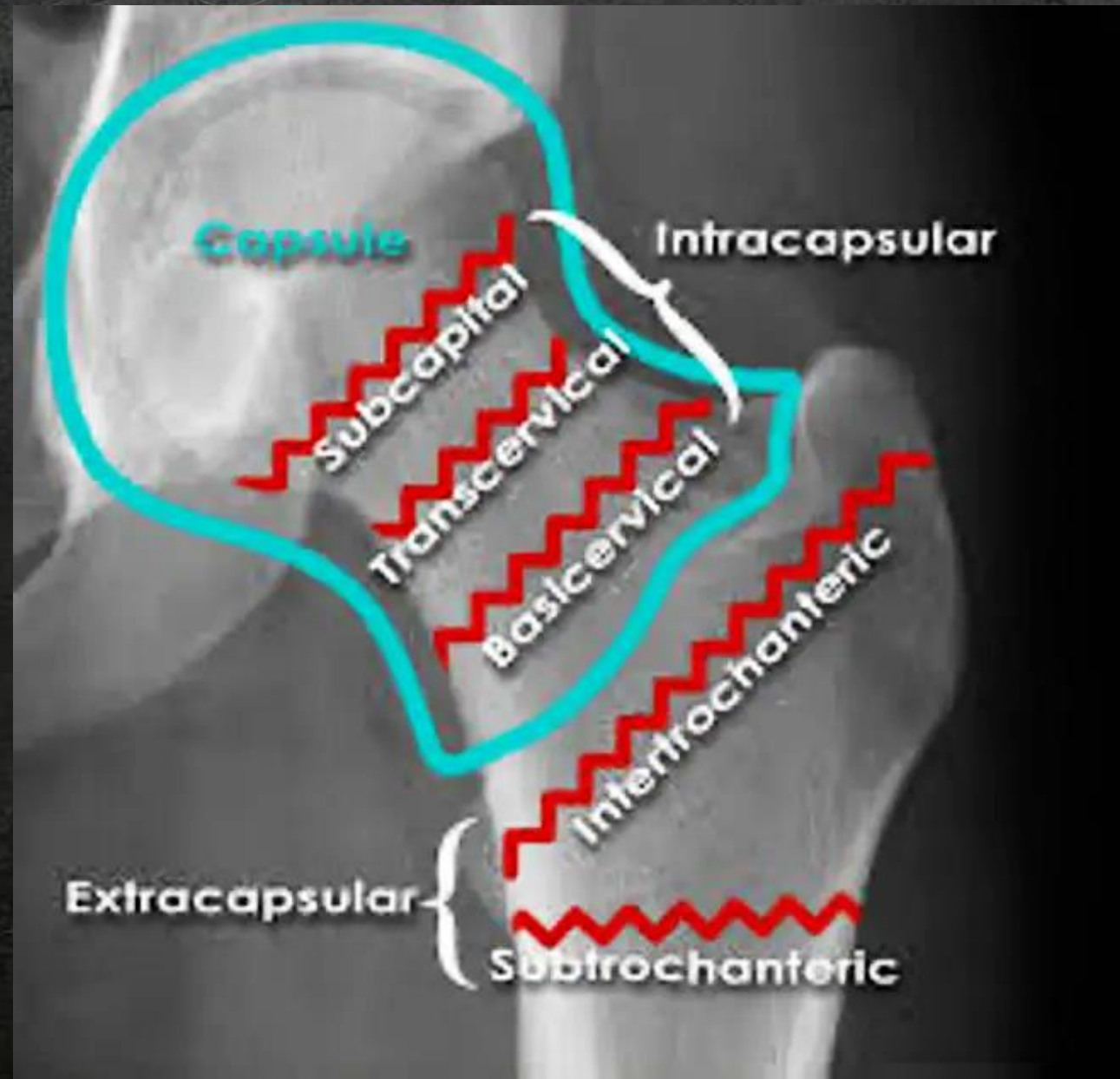Basicervical

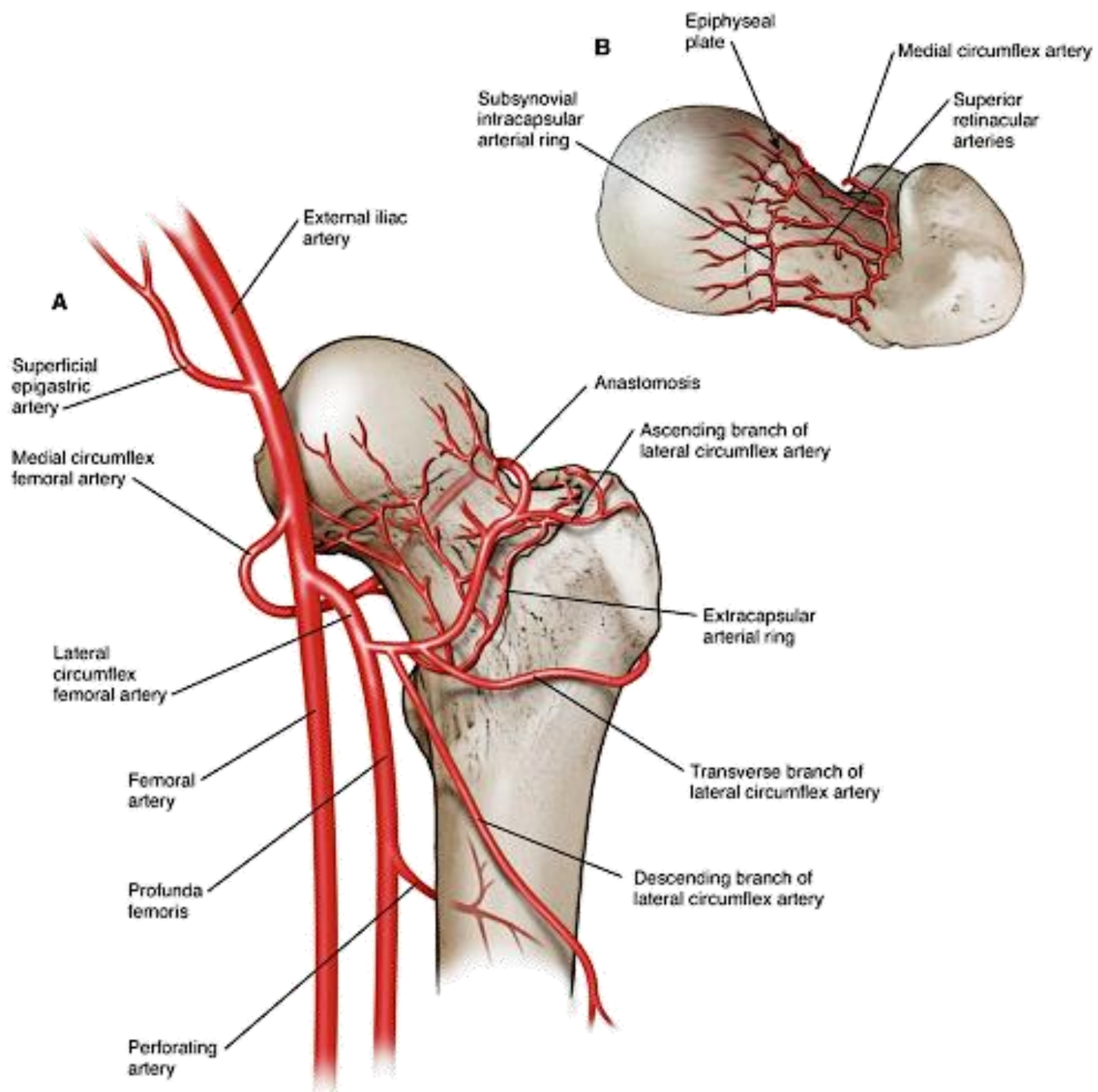
GT

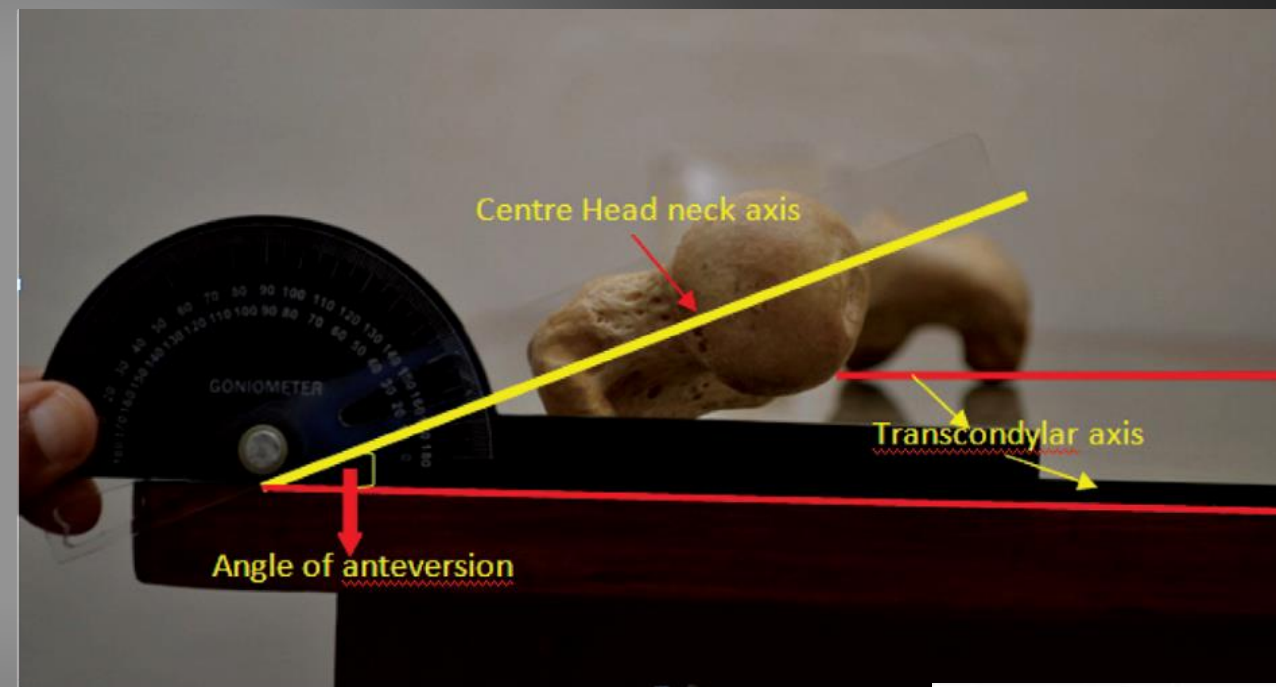

Intertrochanteric

Subtrochanteric

5 cm







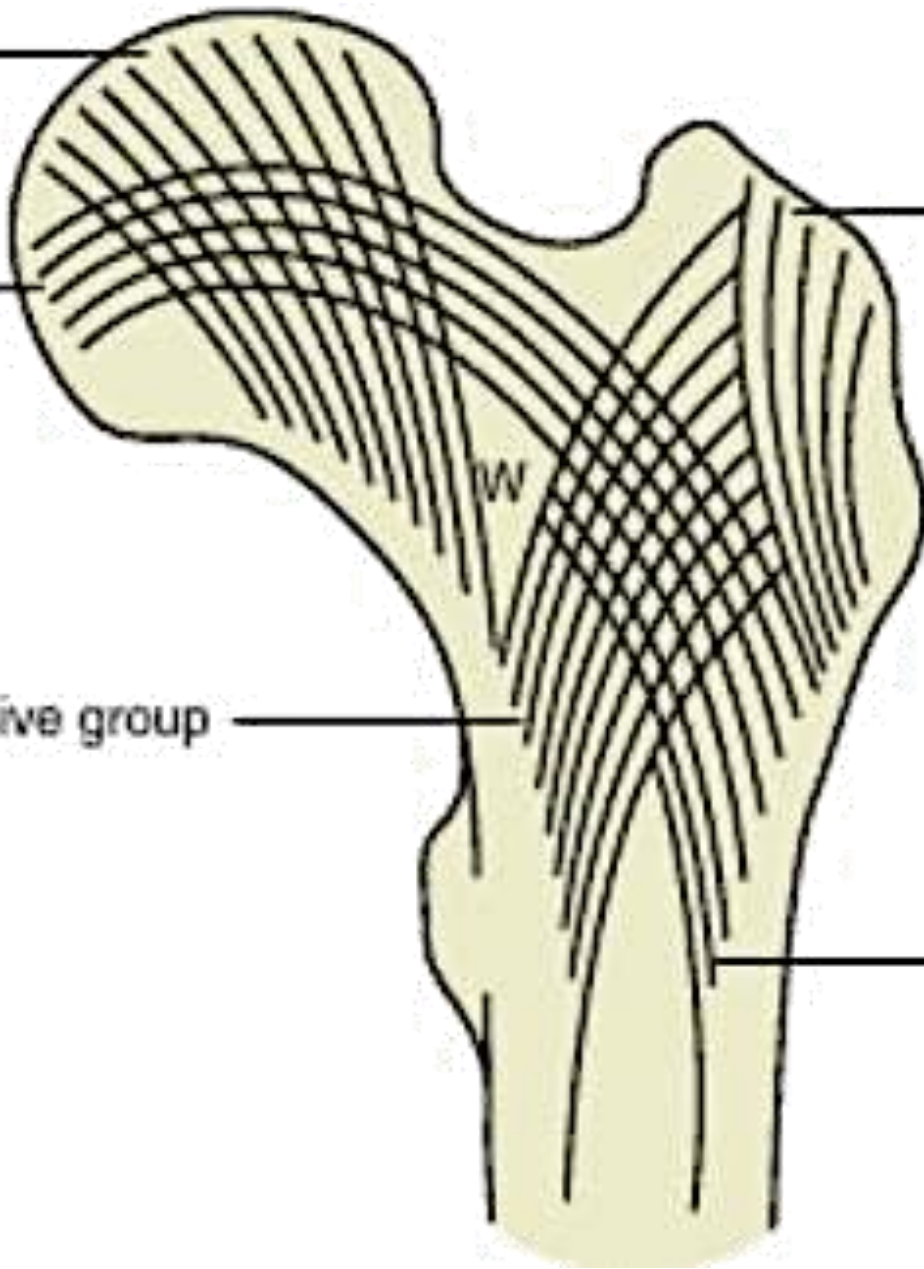
Principal compressive group

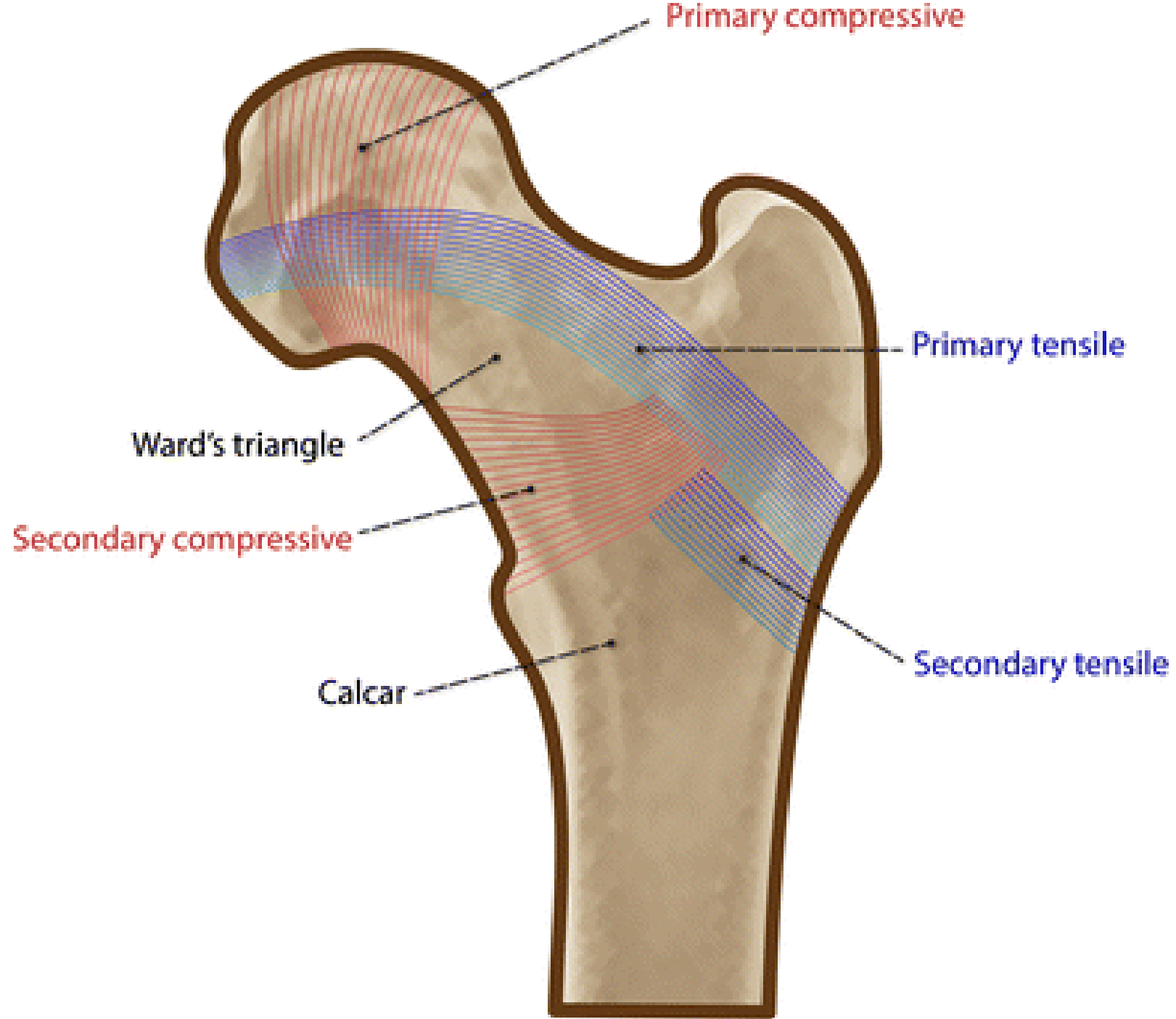
Principal tensile group

Secondary compressive group

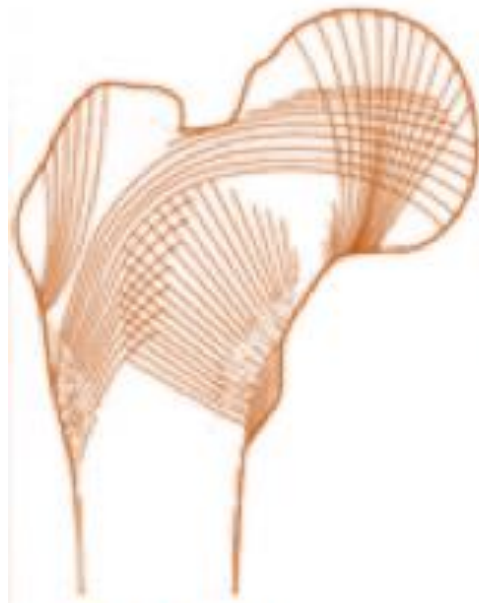
Greater trochanter group

Secondary tensile group

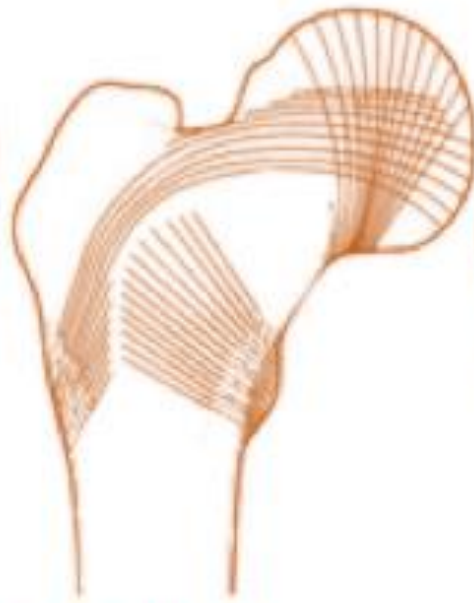




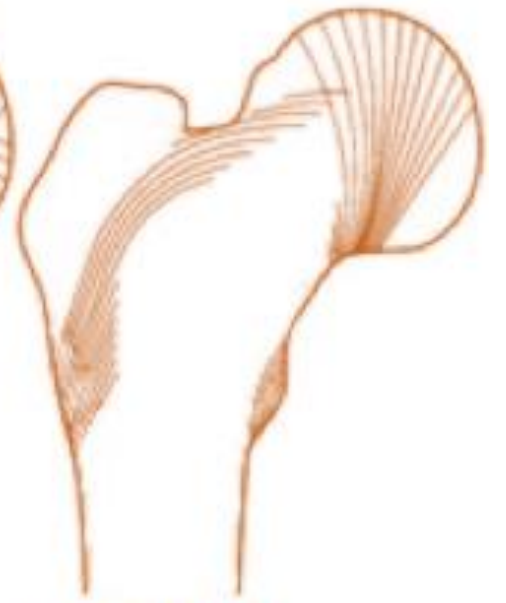Singh's Index



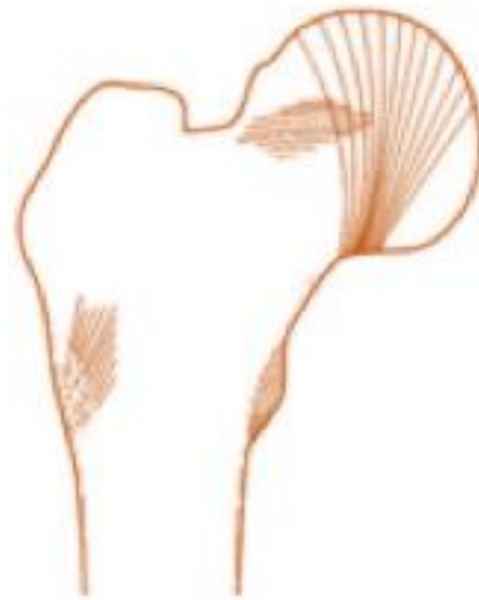Grade VI



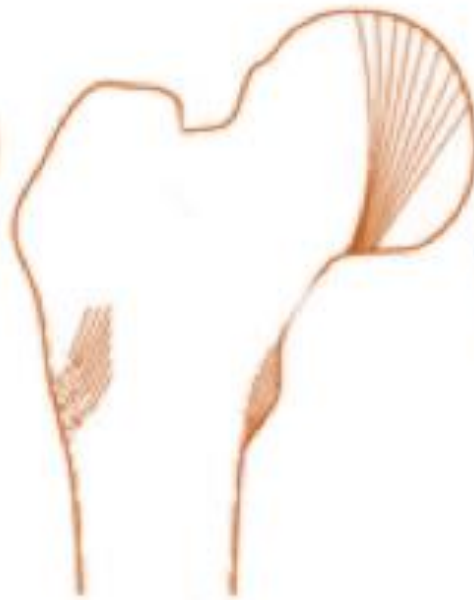Grade V



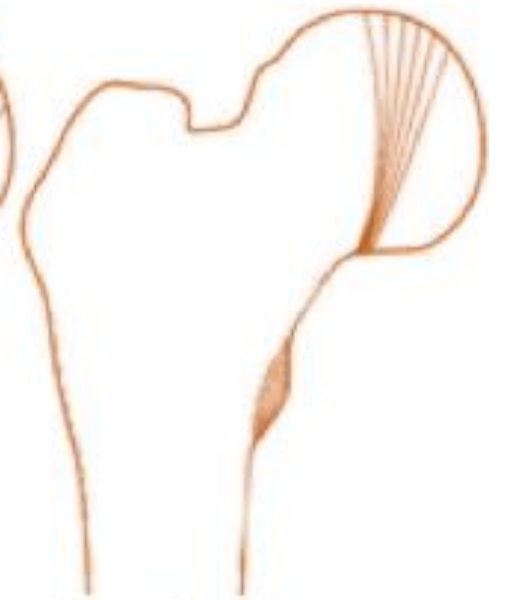Grade IV



Grade III



Grade II



Grade I



> J Bone Joint Surg Am. 1970 Apr;52(3):457-67.

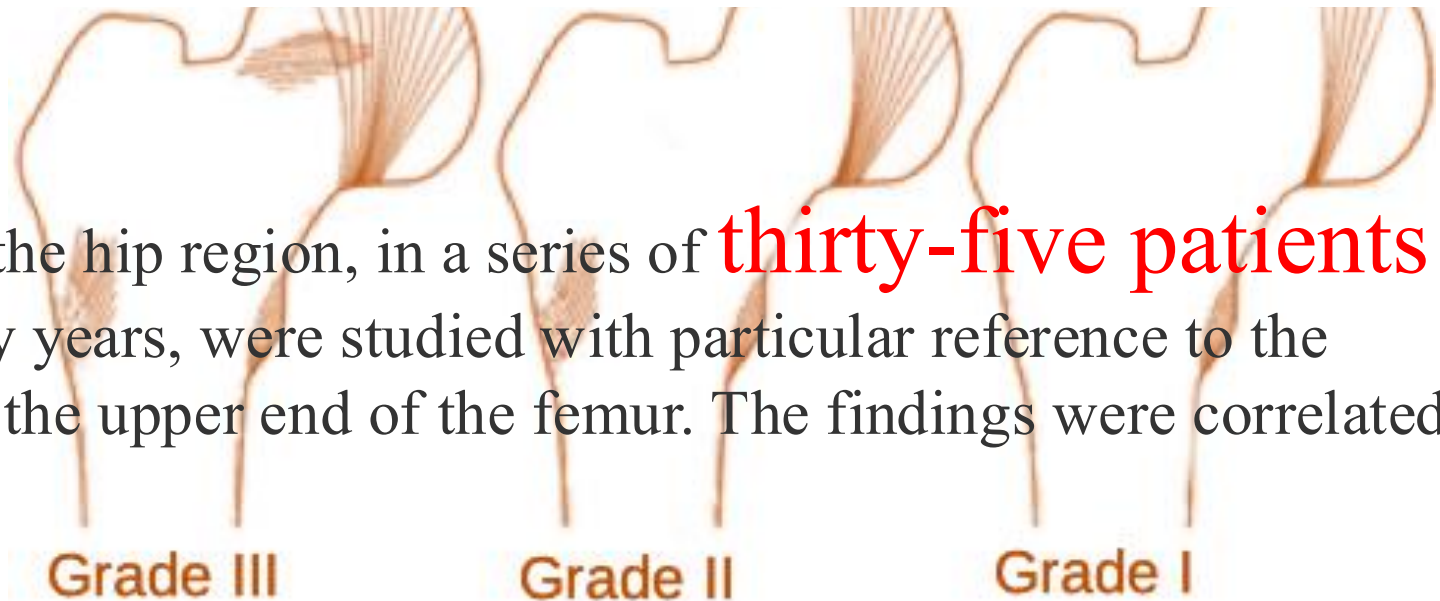
Changes in trabecular pattern of the upper end of the femur as an index of osteoporosis

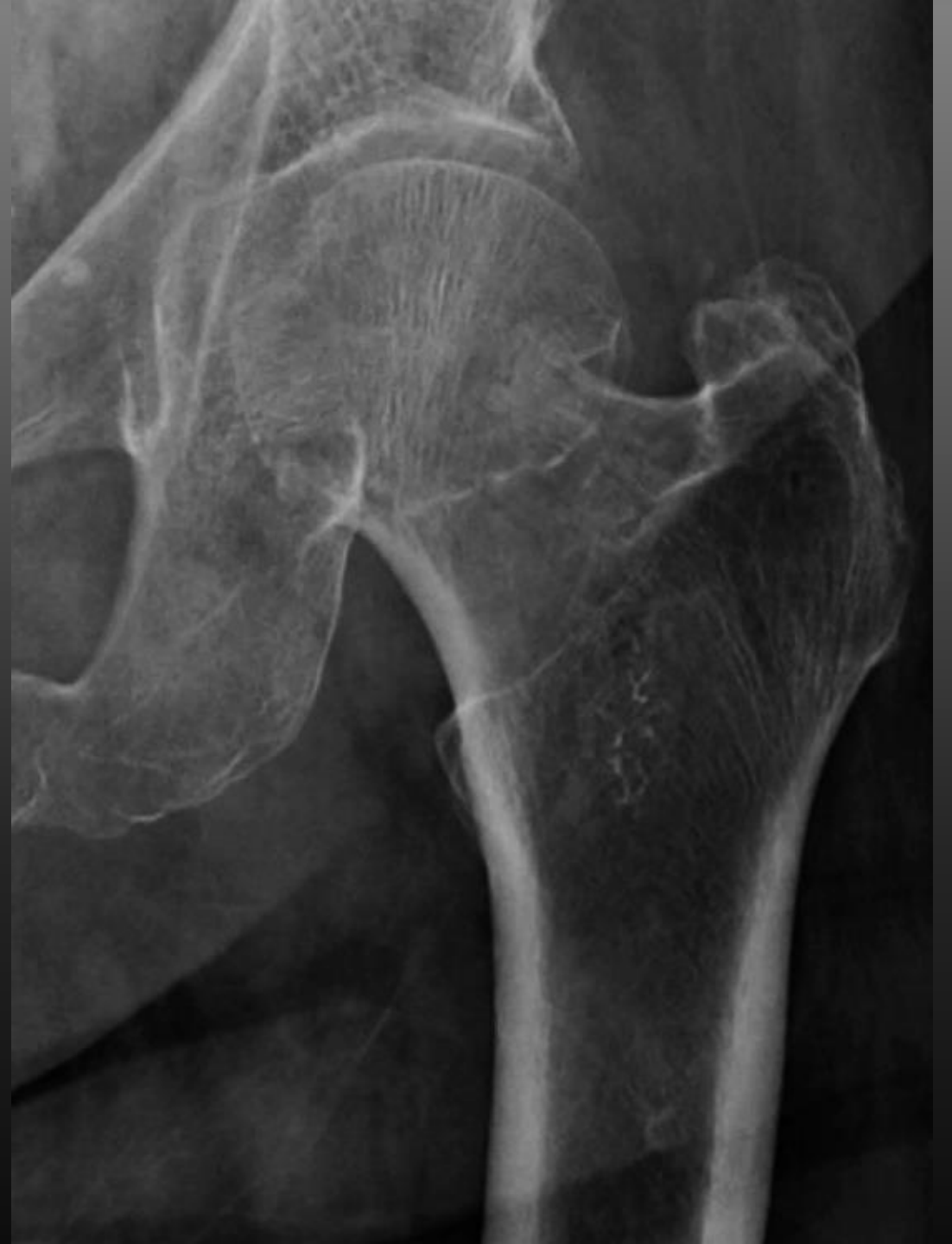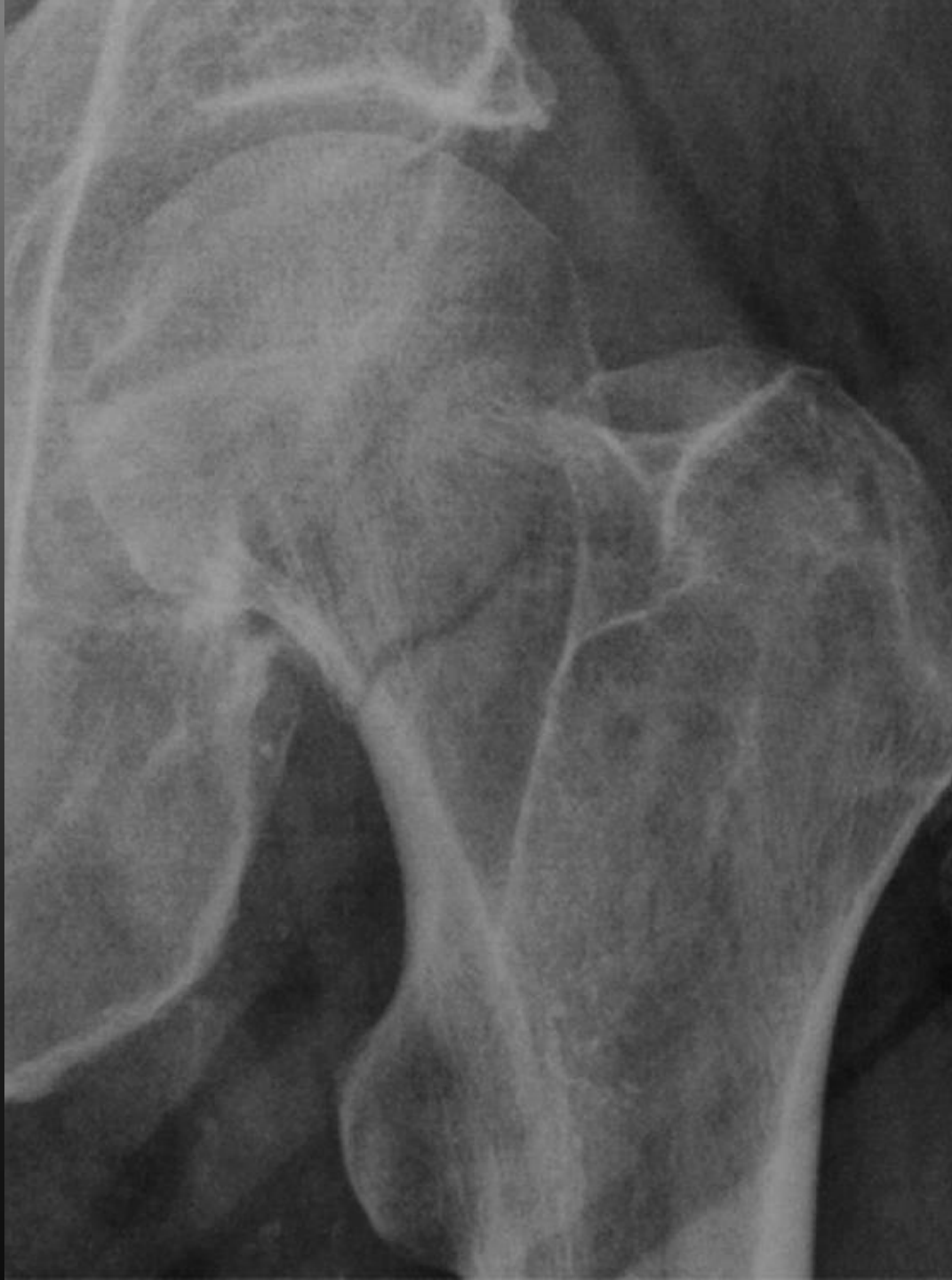M Singh, A R Nagrath, P S Maini

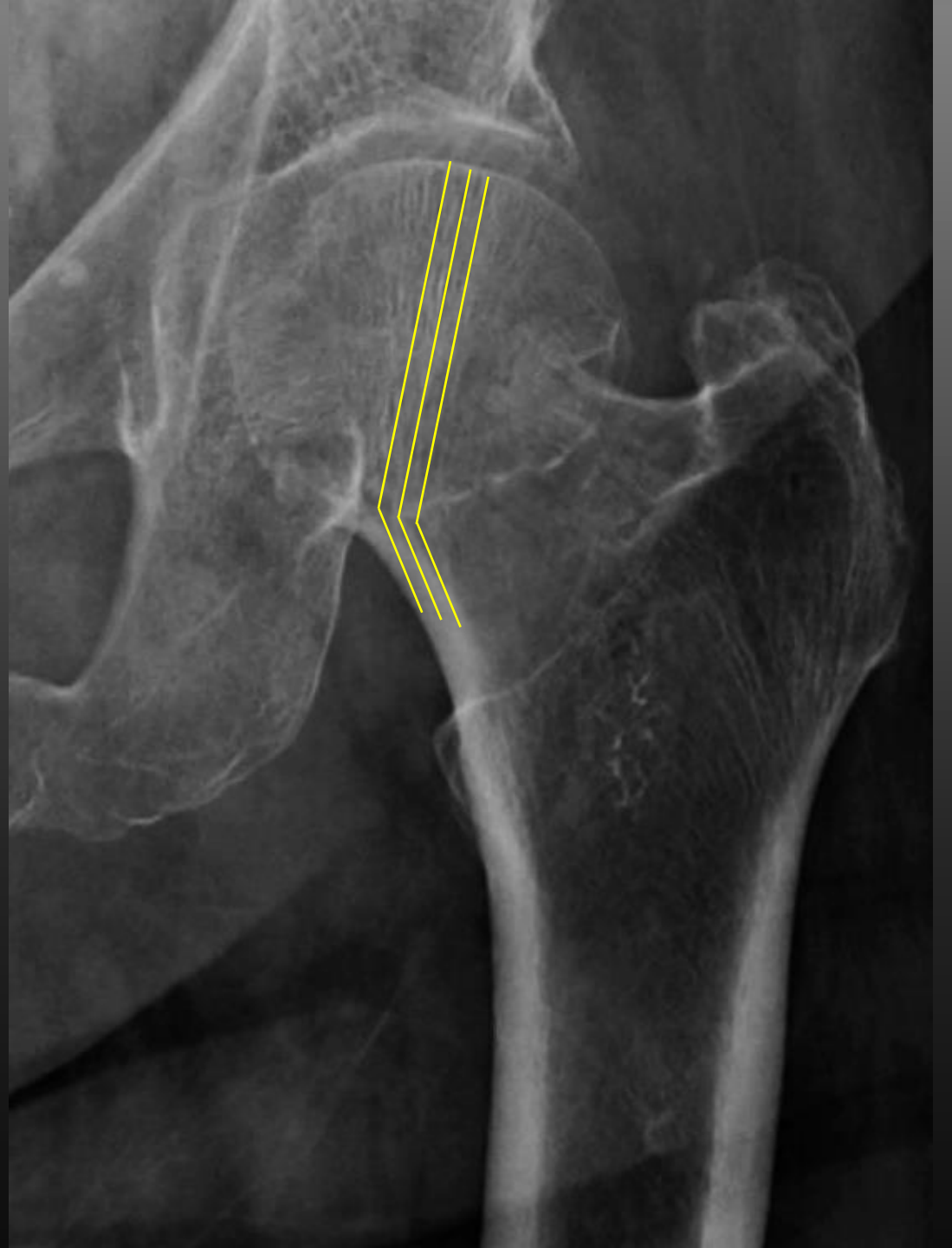
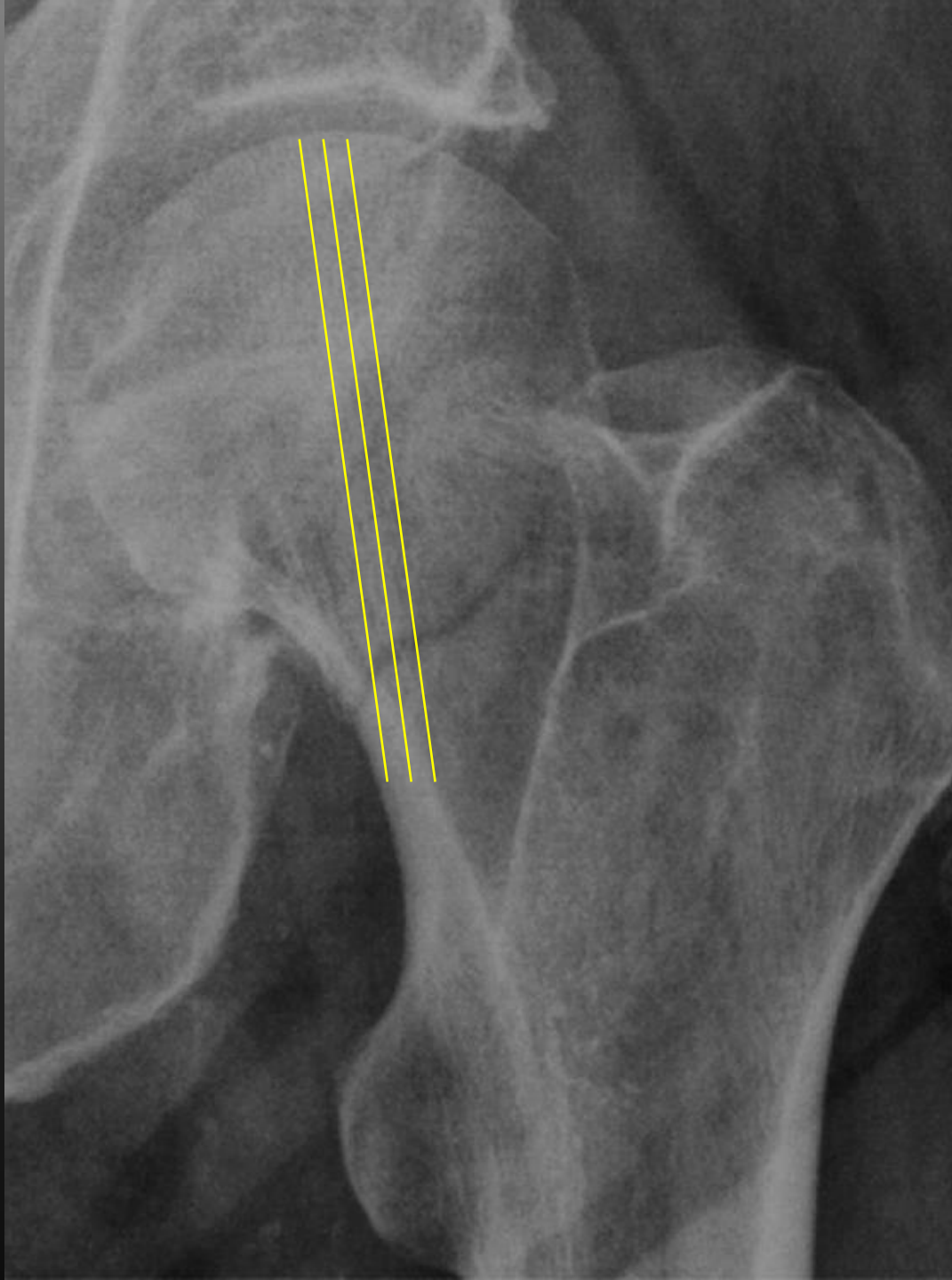
PMID: 5425640

Abstract

Roentgenograms of the hip region, in a series of **thirty-five patients** above the age of fifty years, were studied with particular reference to the trabecular pattern of the upper end of the femur. The findings were correlated

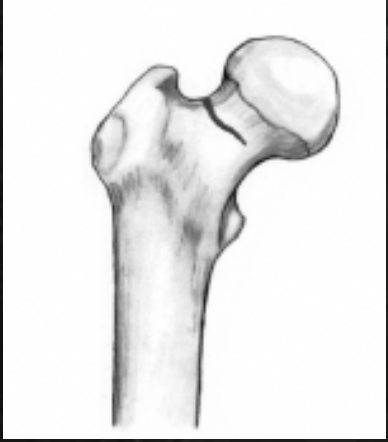





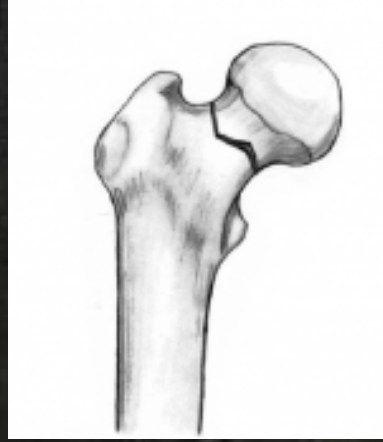Structural Classification

स्ट्रक्चरल क्लासिफिकेशन



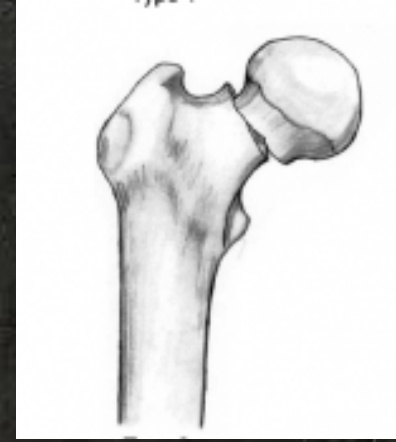
Impacted Fracture

इम्पैक्टड फ्रैक्चर



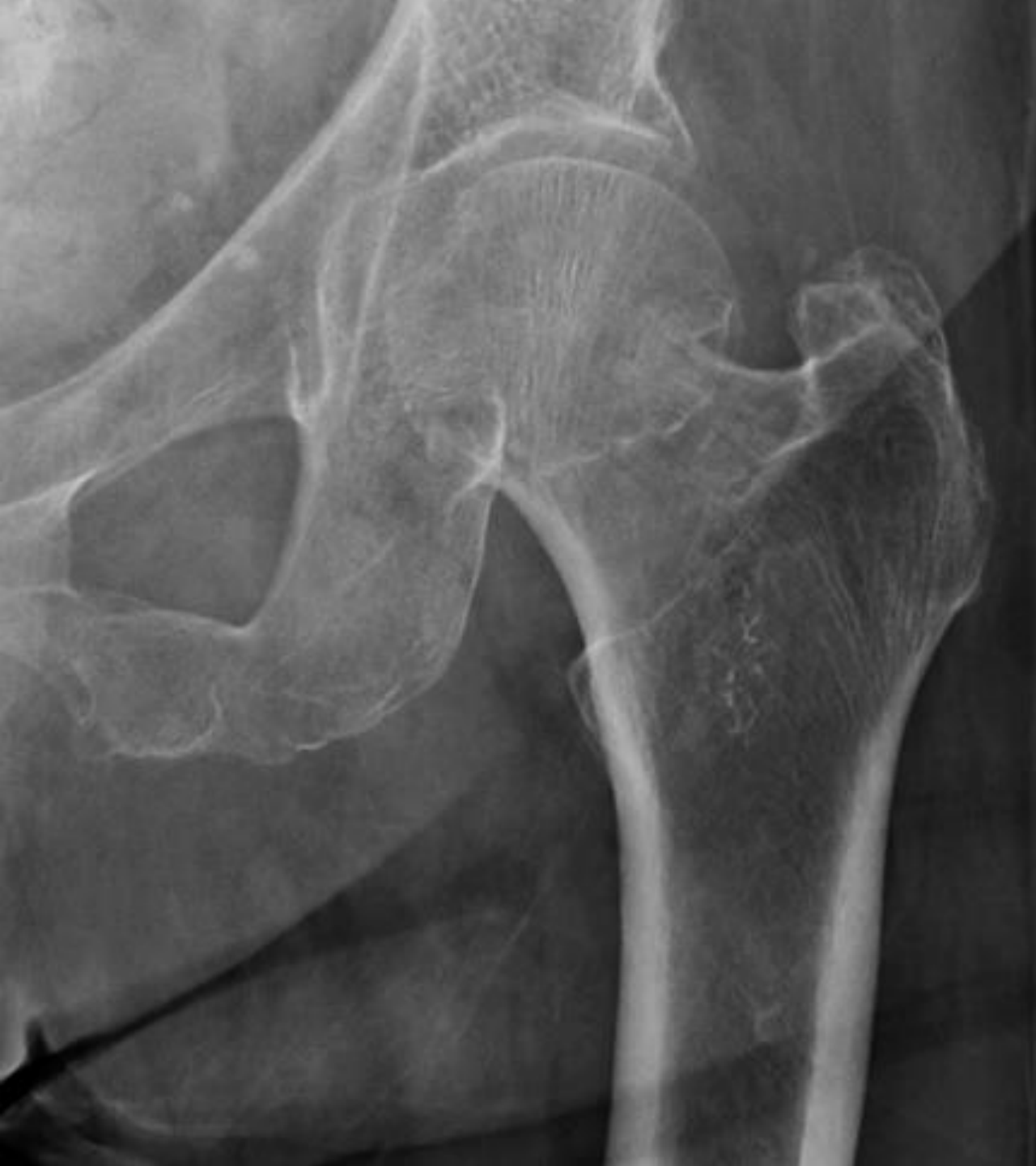Undisplaced Fracture

अनडिस्प्लेस्ड फ्रैक्चर



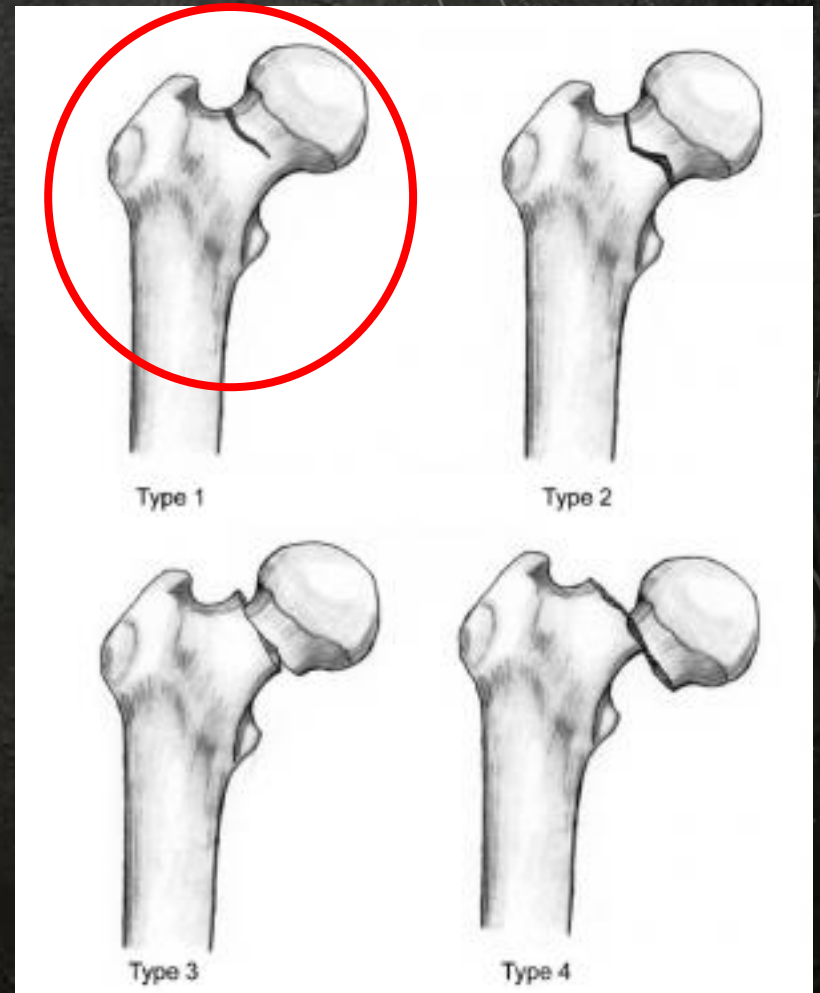
Displaced Fracture

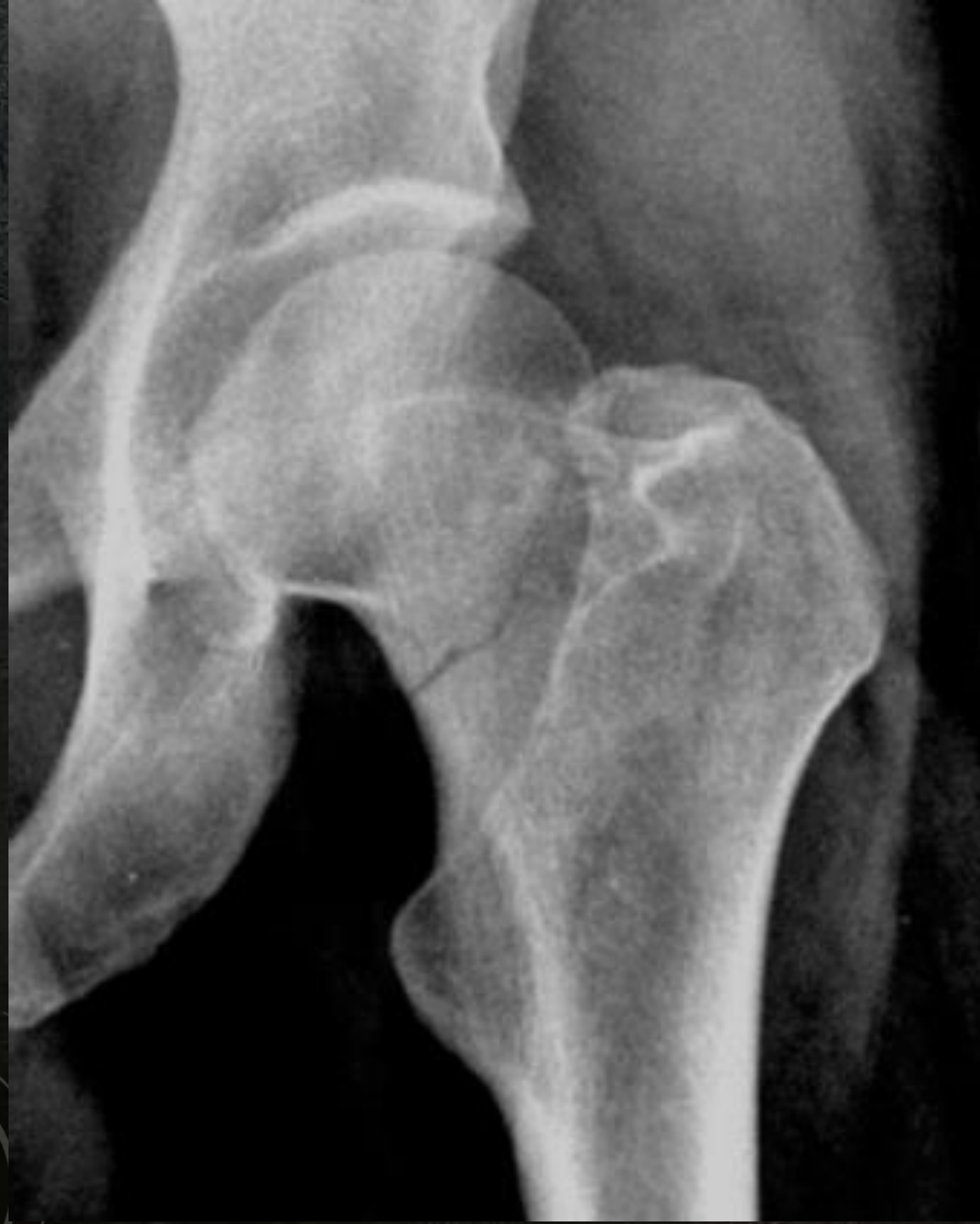डिस्प्लेस्ड फ्रैक्चर



Impacted Fracture

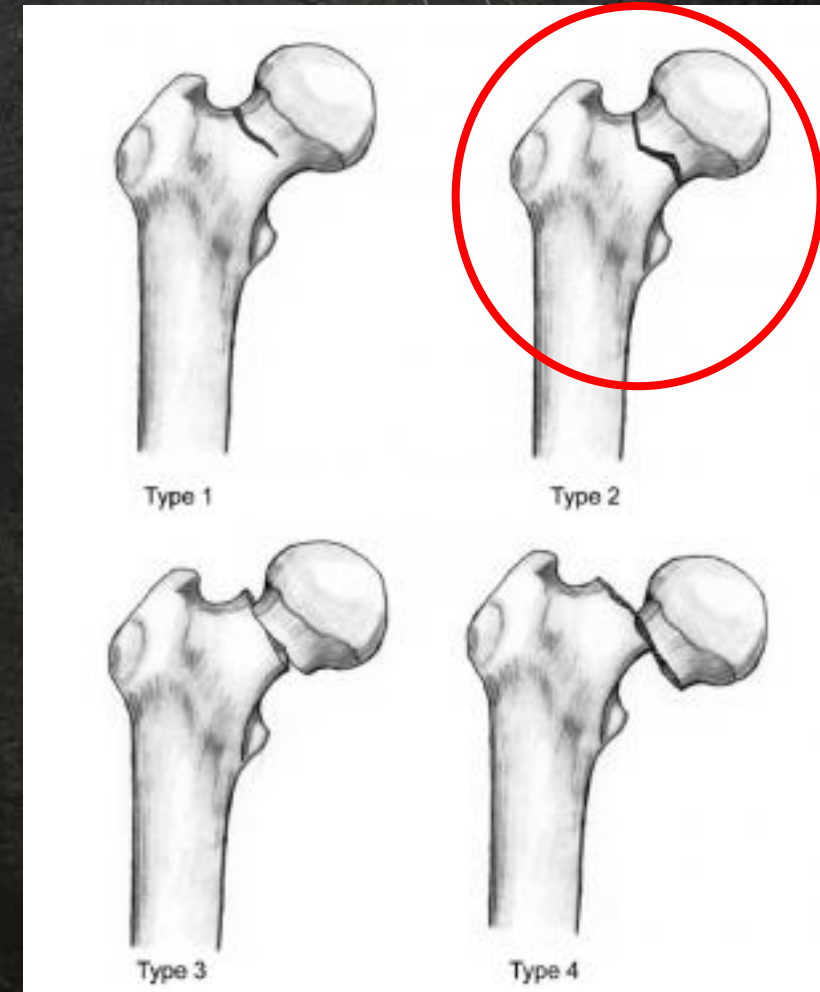
इम्पैक्टेड फ्रैक्चर





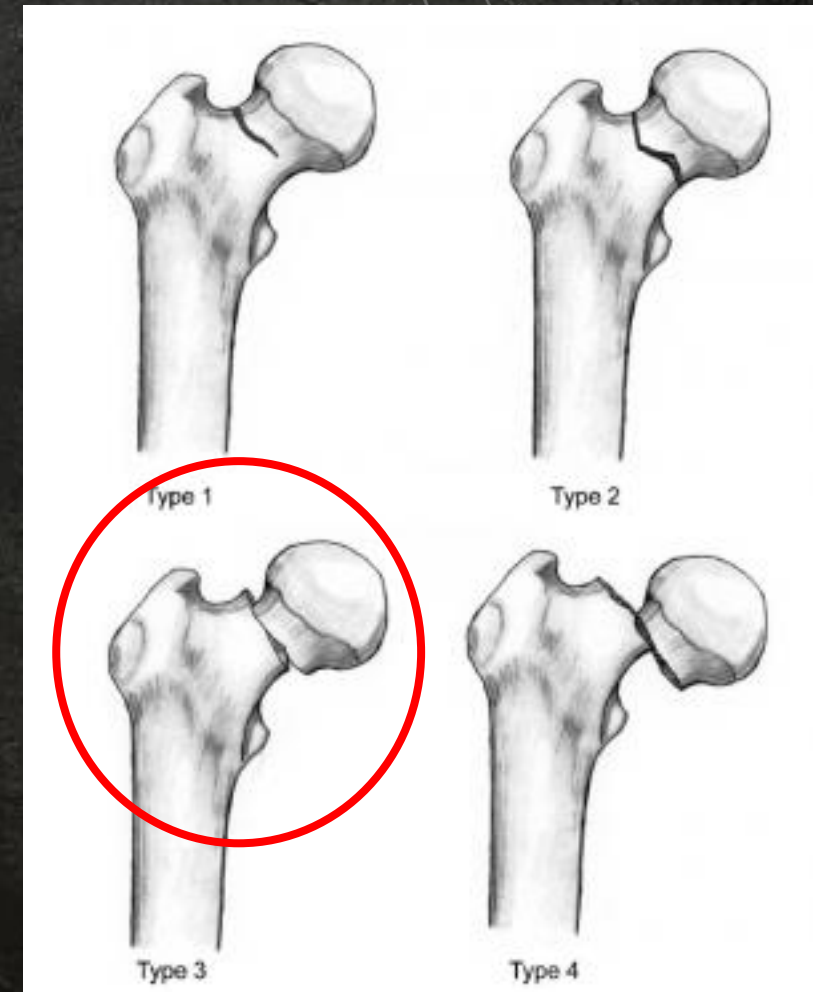
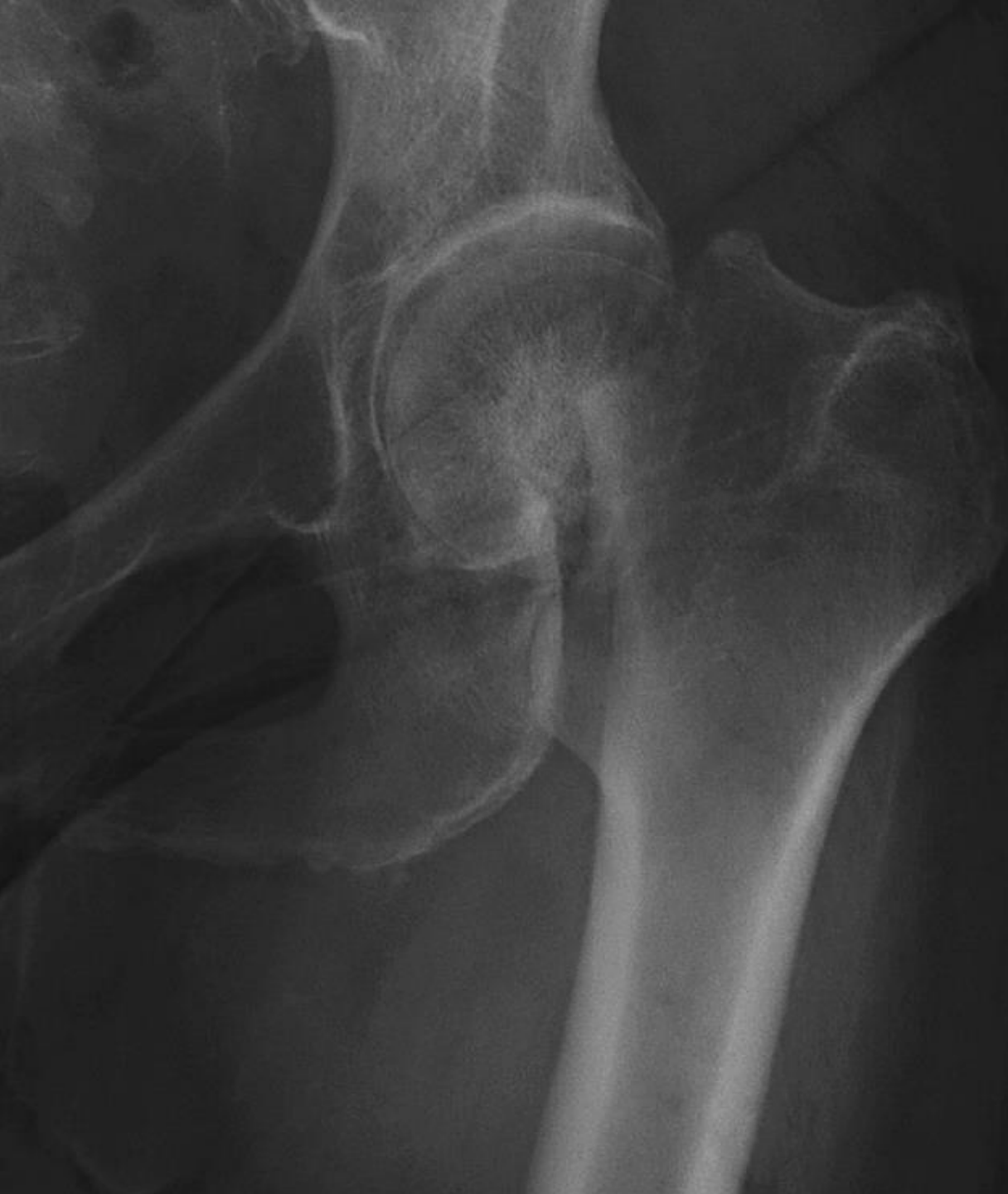Undisplaced Fracture

अनडिस्प्लेस्ड फ्रैक्चर



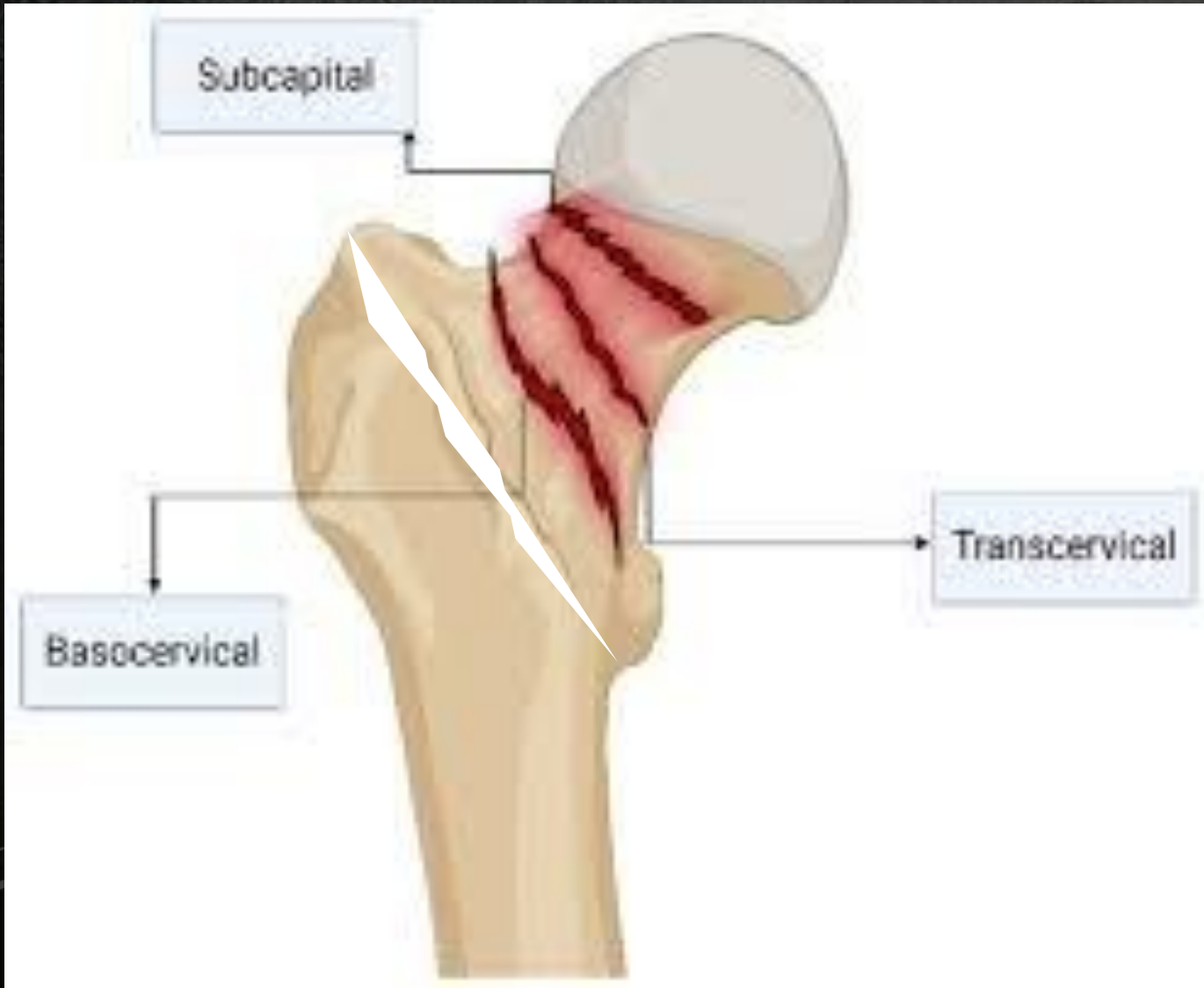Displaced Fracture

डिस्प्लेस्ड फ्रैक्चर



Anatomical Classification

एनाटॉमिकल क्लासिफिकेशन



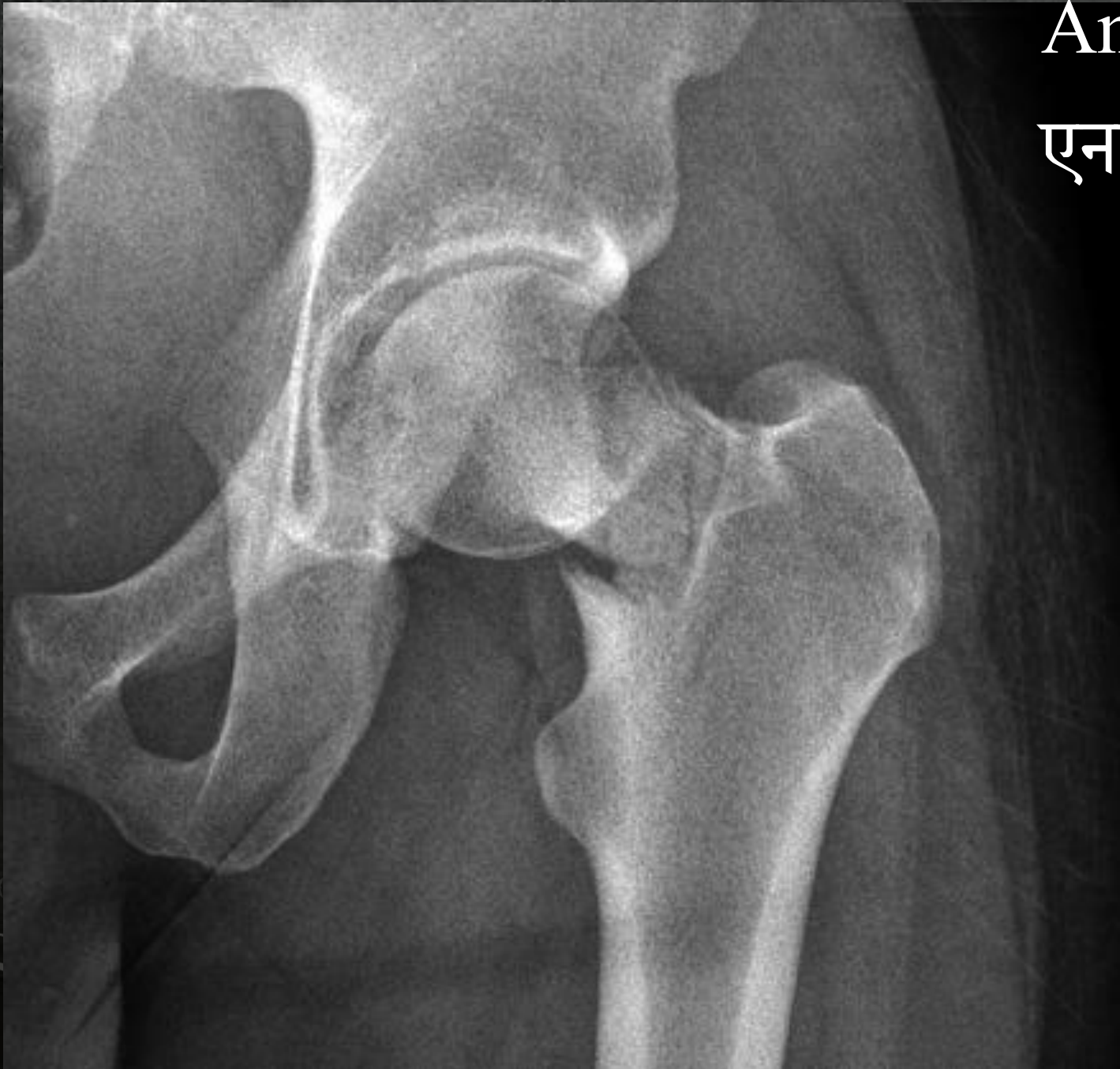

Anatomical Classification

एनाटॉमिकल क्लासिफिकेशन

Sub capital Fracture

सब कैपिटल फ्रैक्चर

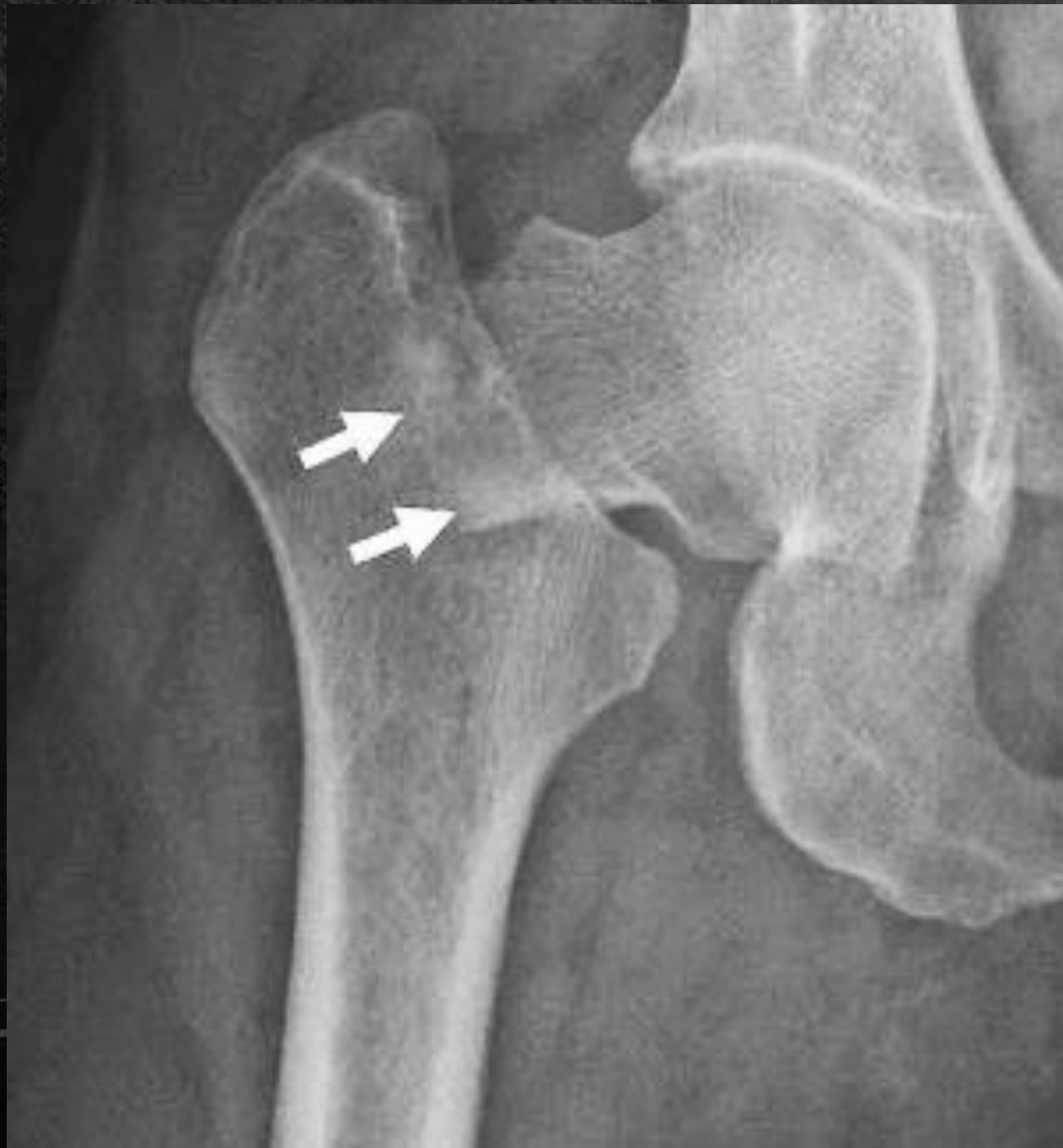

Anatomical Classification

एनाटॉमिकल क्लासिफिकेशन

Trans Cervical Fracture

ट्रांस सर्वाइकल फ्रैक्चर



Anatomical Classification

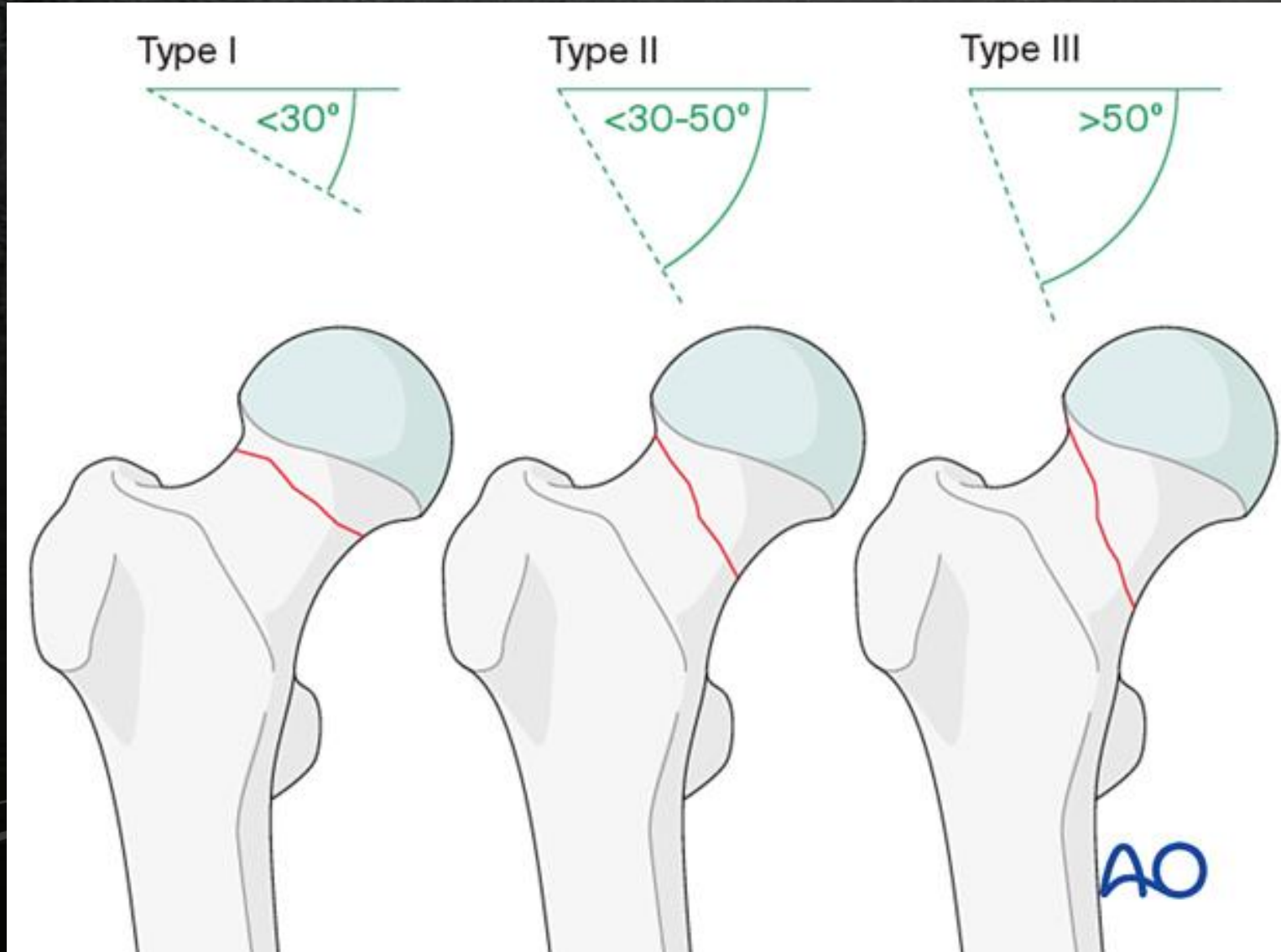
एनाटॉमिकल क्लासिफिकेशन

Basi Cervical Fracture

बेसी सर्वाइकल फ्रैक्चर

Pauwels Classification

पॉवेल्लस क्लासिफिकेशन

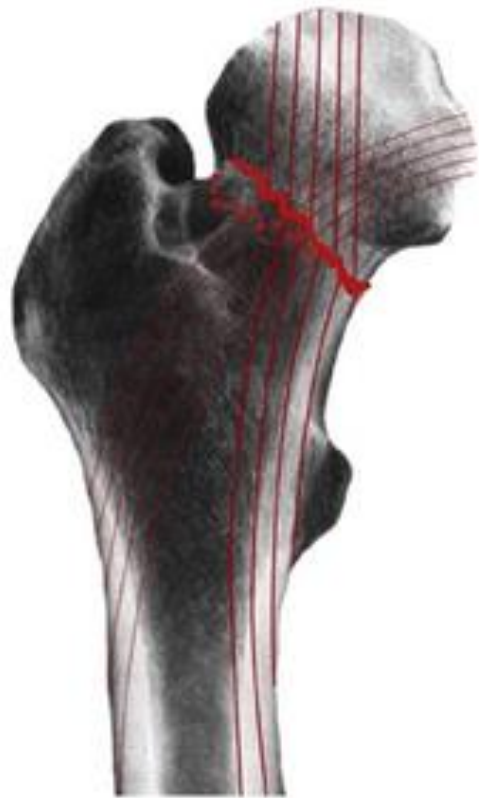

Garden's Classification

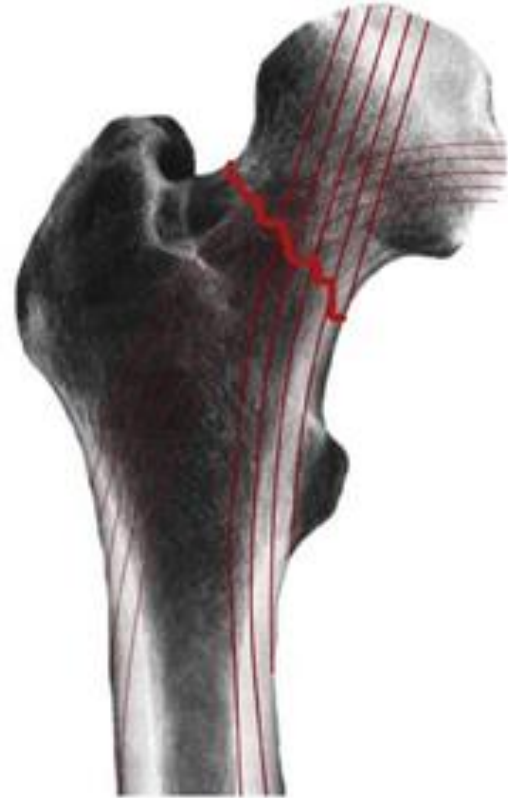गार्डन्स क्लासिफिकेशन

Nondisplaced

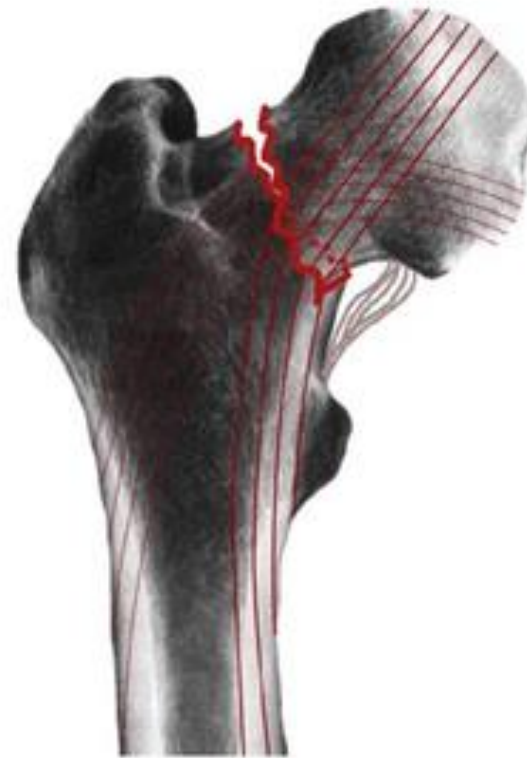Displaced



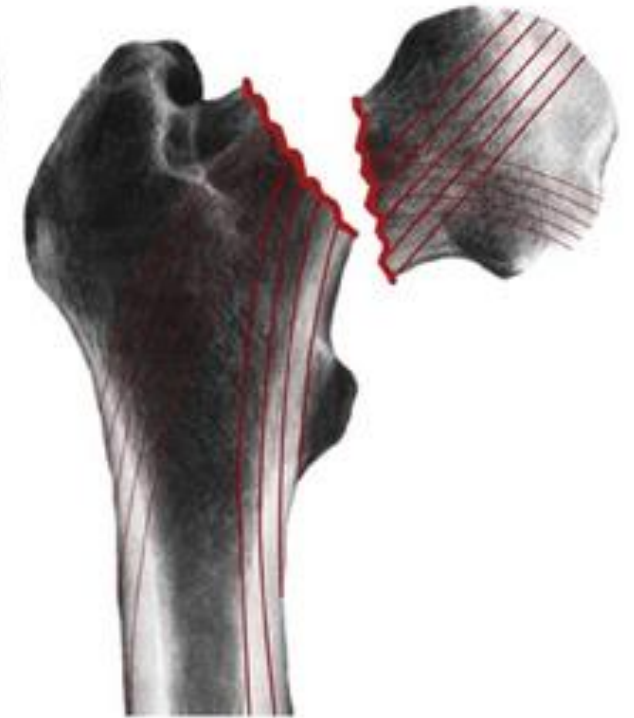Garden I



Garden II



Garden III



Garden IV

Clinical Features

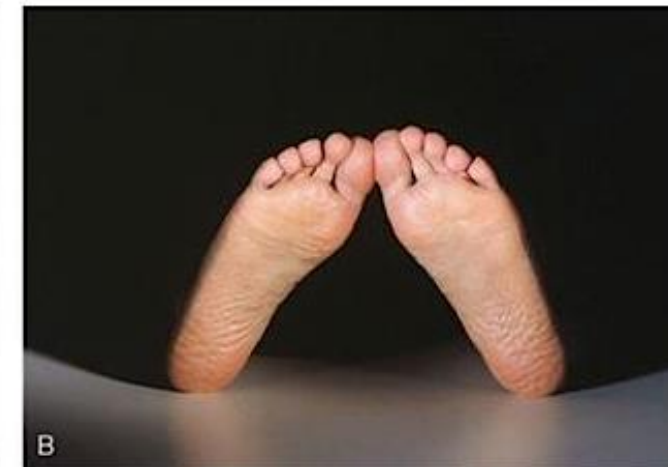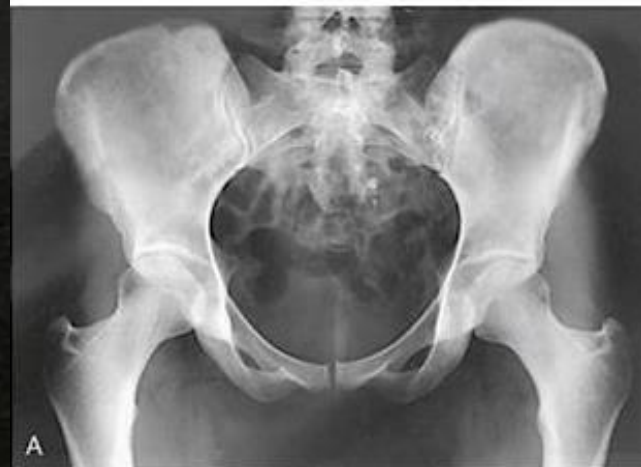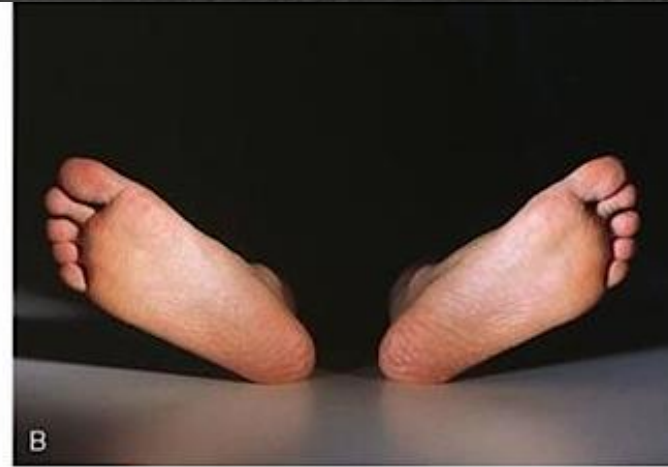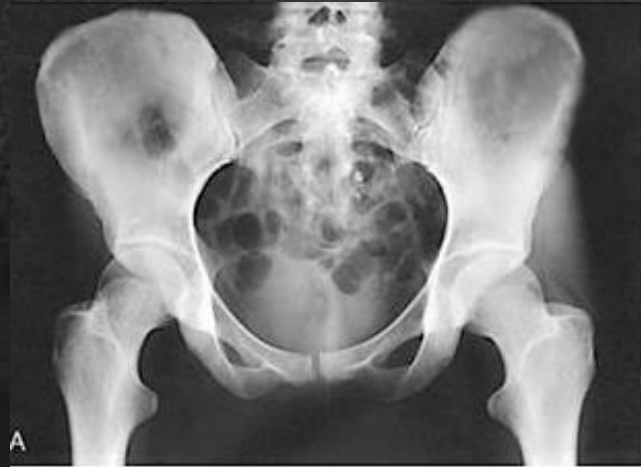नैदानिक लक्षण

- High velocity / Low velocity trauma
- Inability to bear weight
- Pain in groin area
- Tender – Base of Scarpa's Triangle
- External rotation deformity
- Shortening of the limb
- Painful Hip Movement
- Active SLR not possible
- उच्च वेग / निम्न वेग आघात
- वजन सहन करने में असमर्थता
- ग्रॉइन एरिया में दर्द
- टेंडर - स्कार्पा त्रिभुज का आधार
- एक्सटर्नल रोटेशन विकृति
- पैर की लंबाई में कमी होना
- हिप जॉइंट के मूवमेंट में दर्द
- सक्रिय एसएलआर संभव नहीं होना

Investigations

जांच

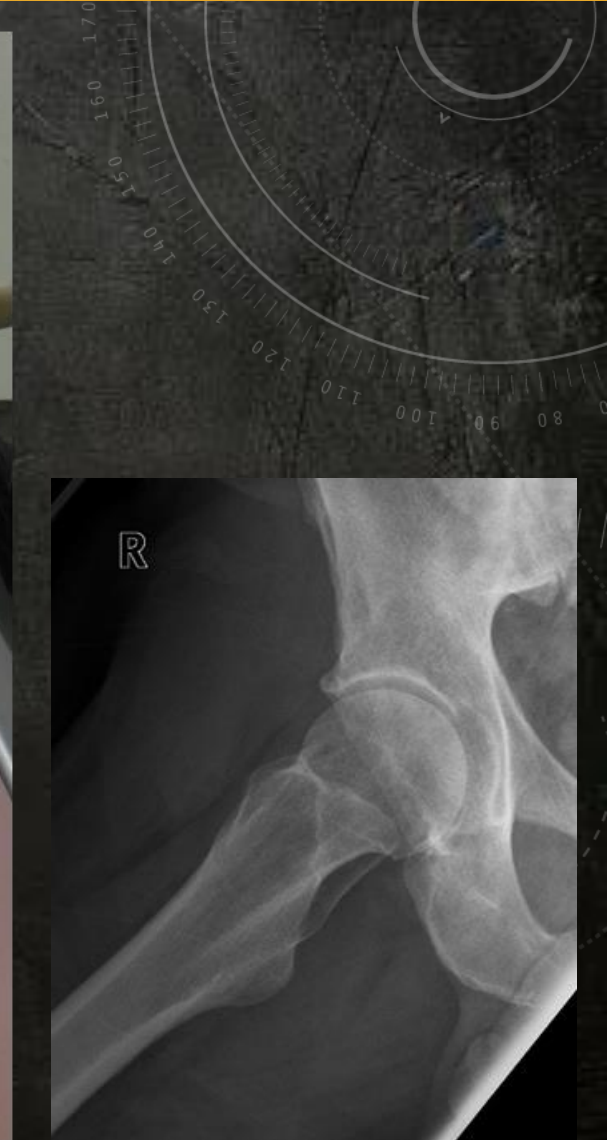
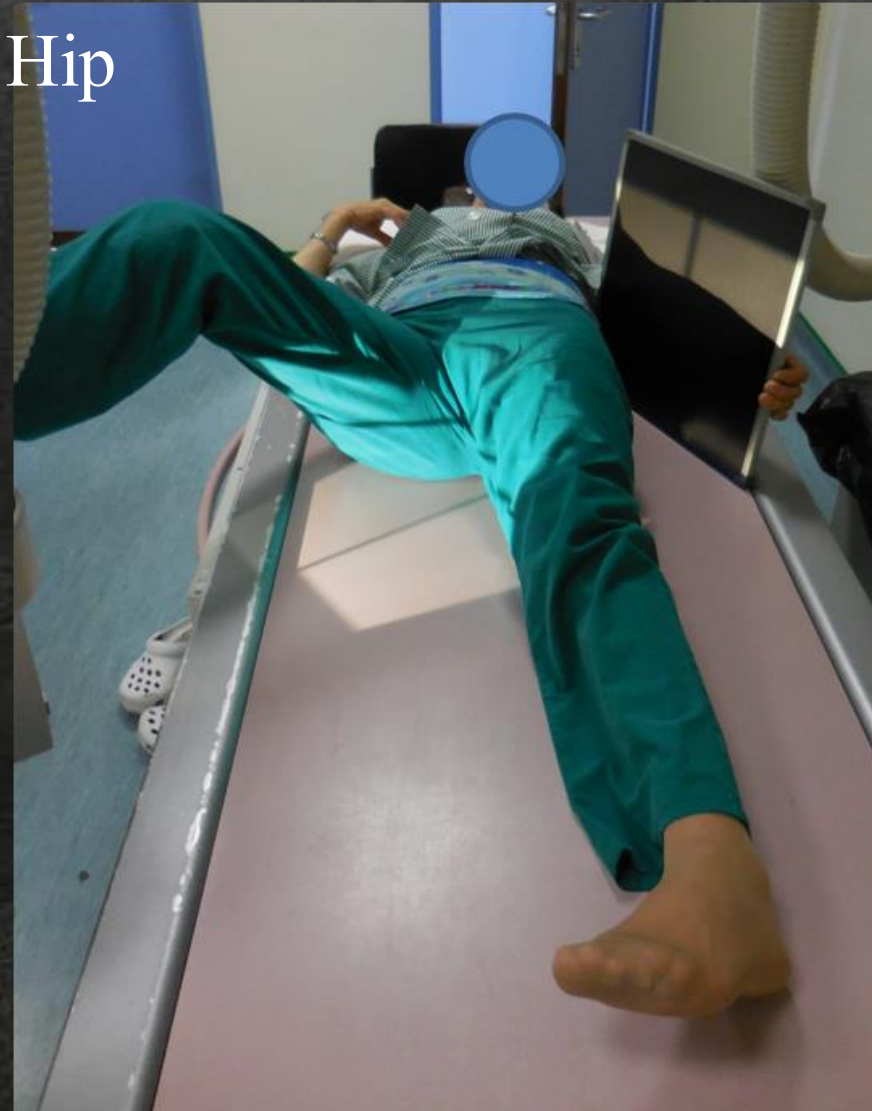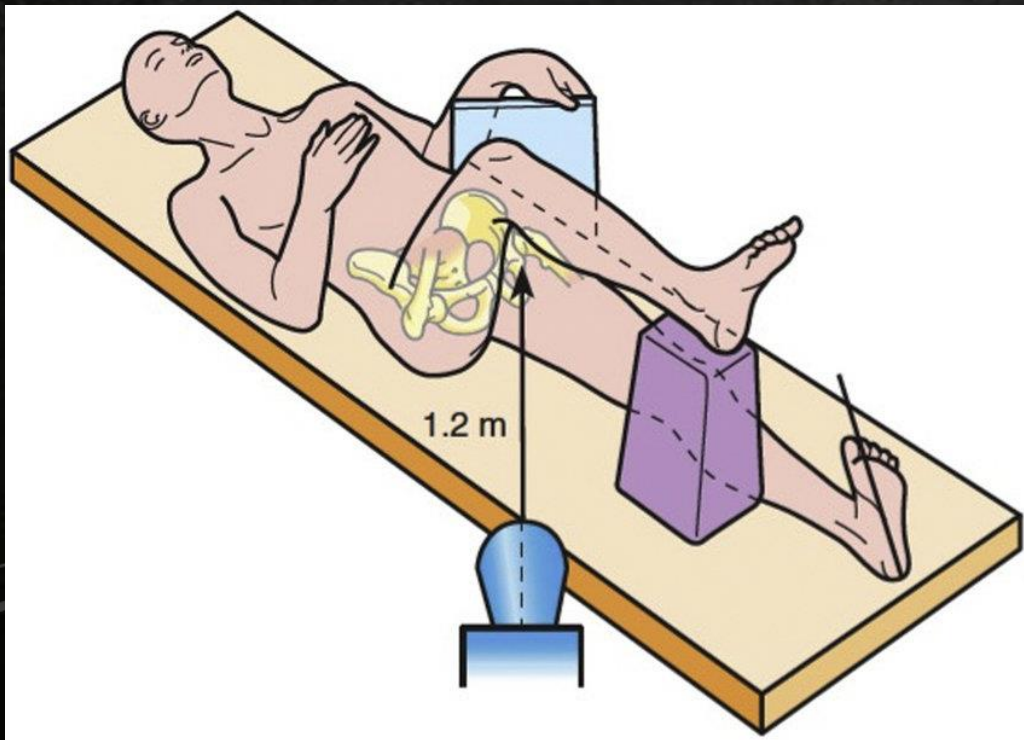
- X ray Pelvis with Both Hips – AP View – in 15 Degree Internal rotation



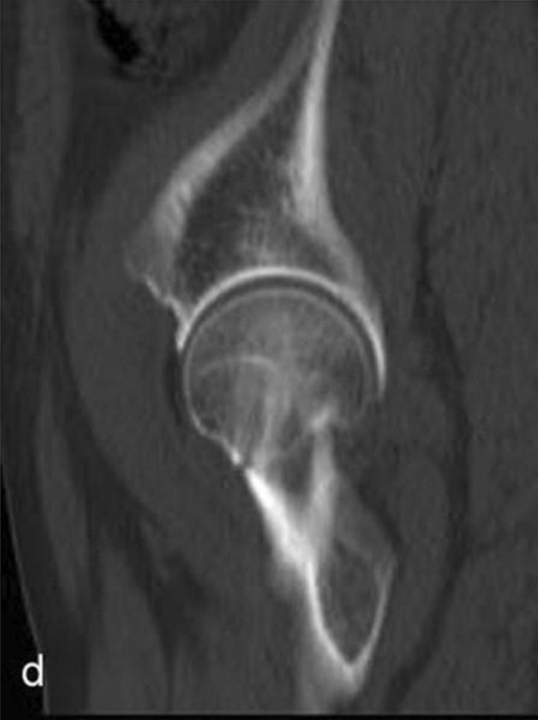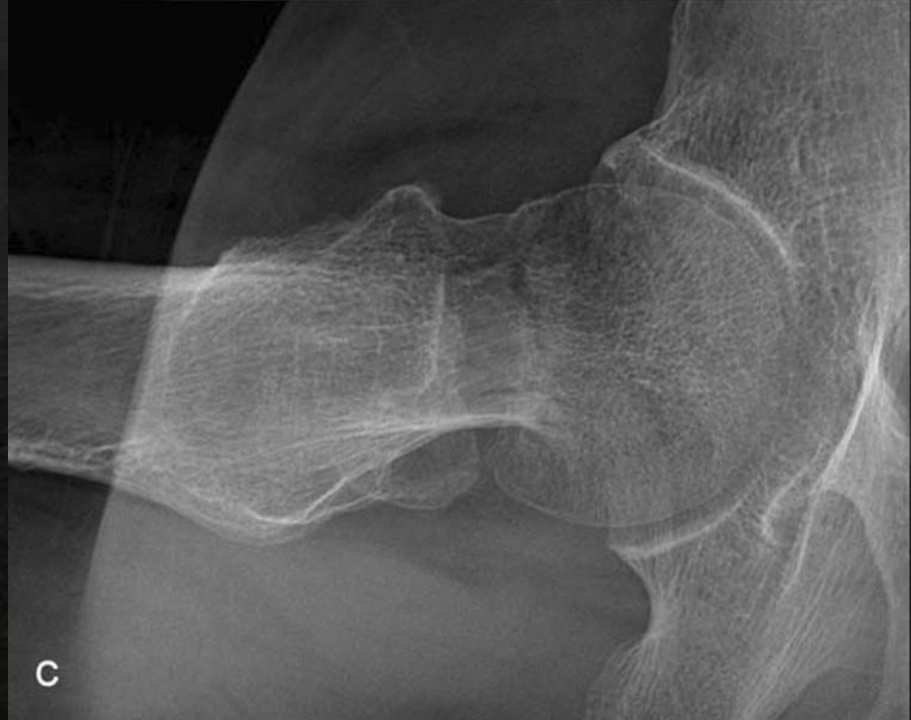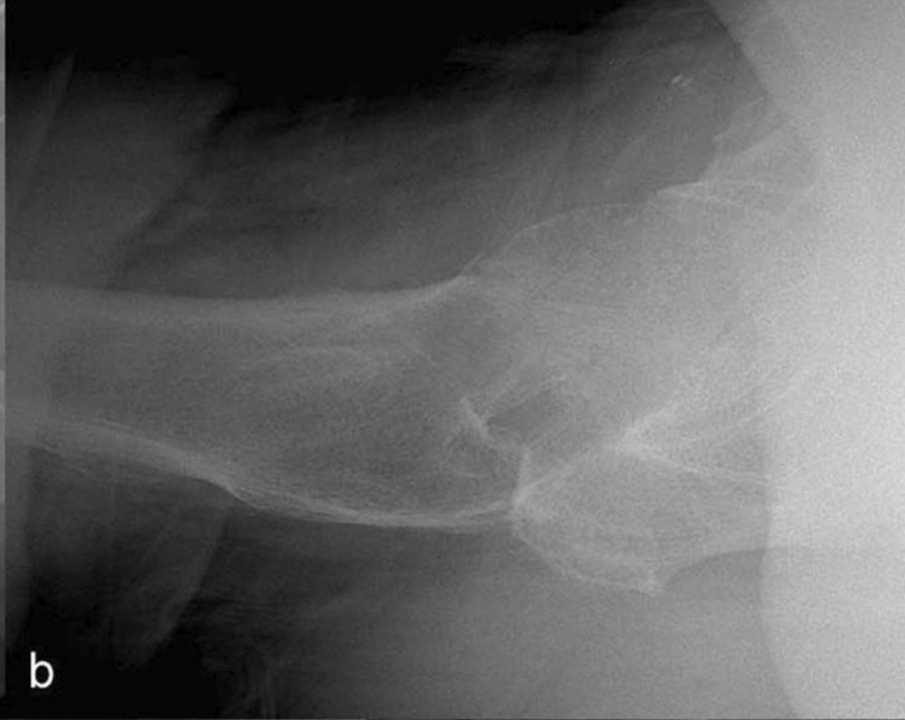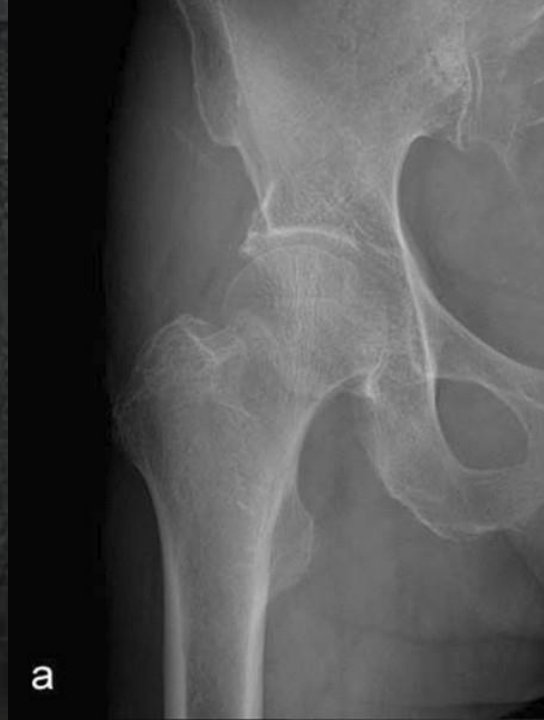Investigations

जांच

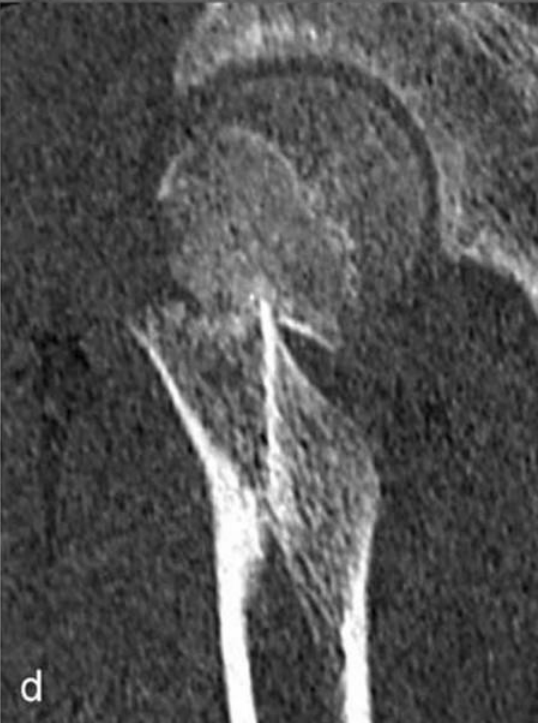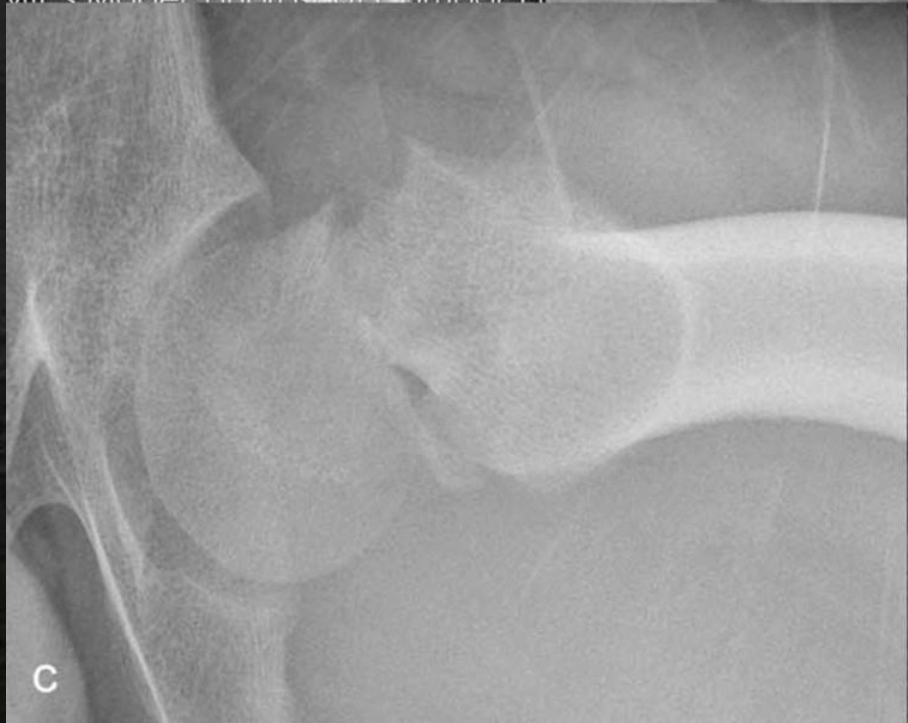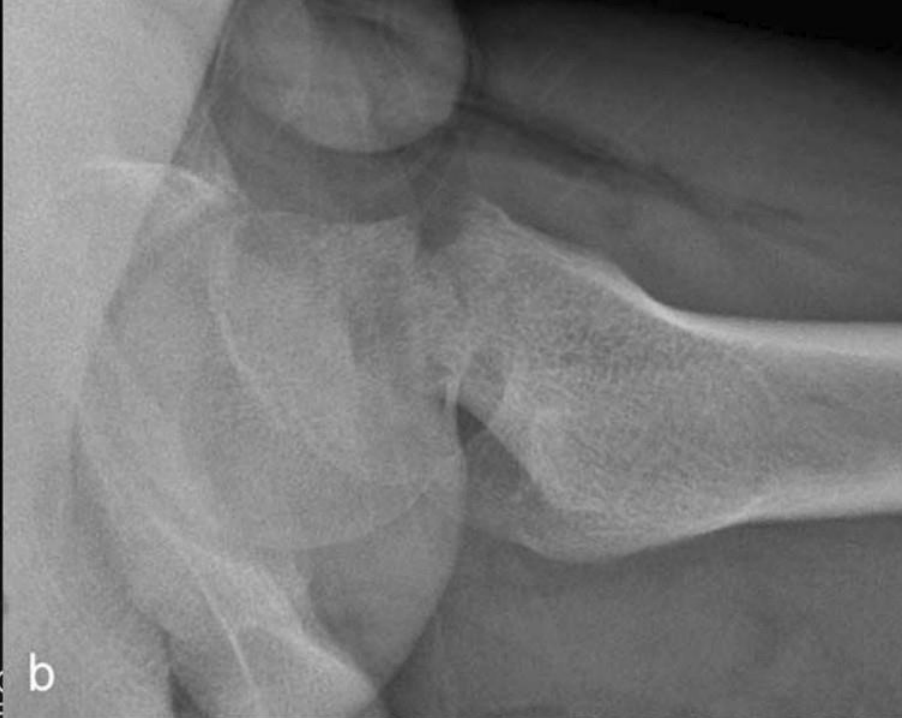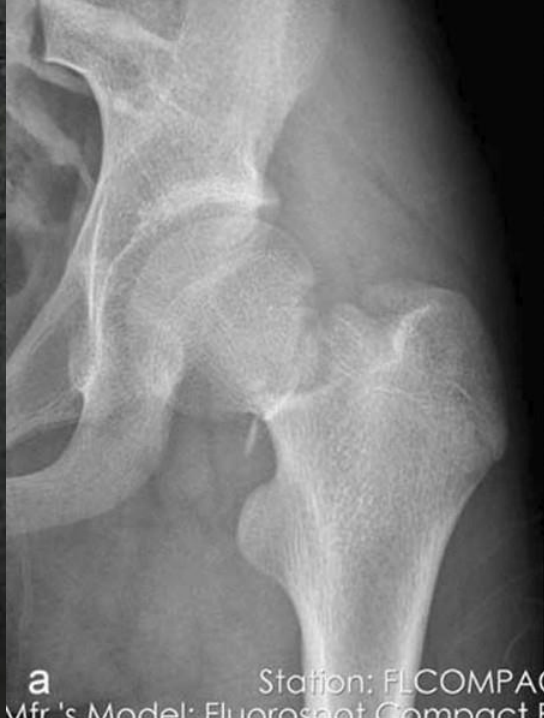- Cross Table Lateral View of Hip



Investigations

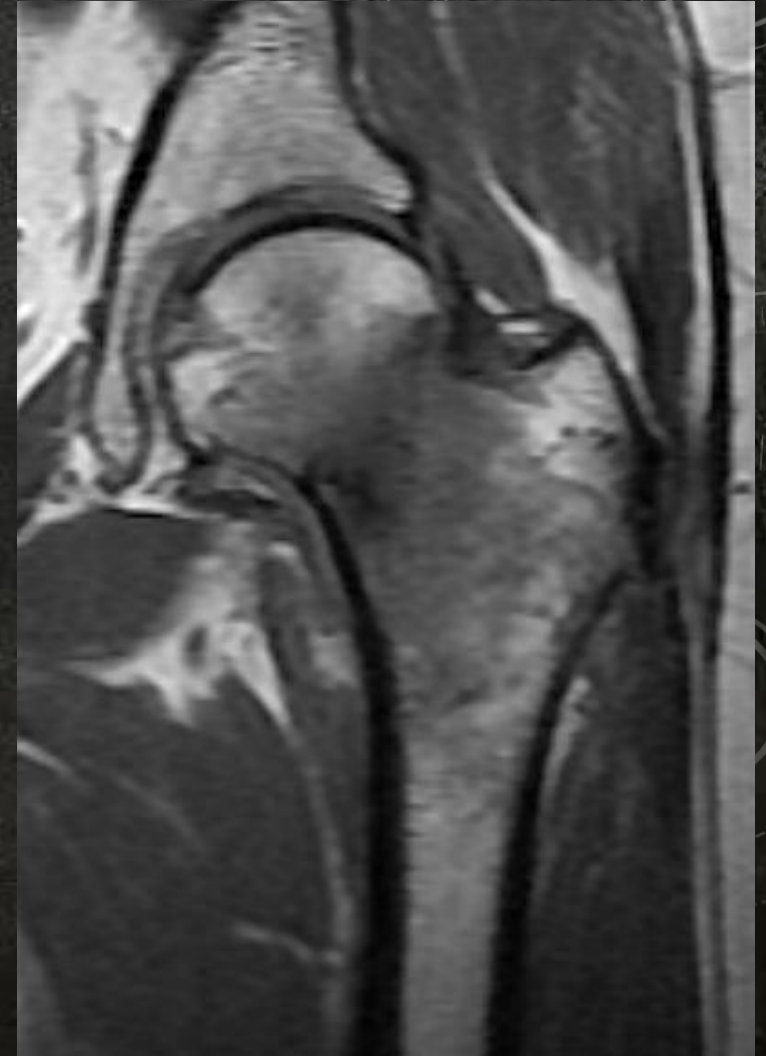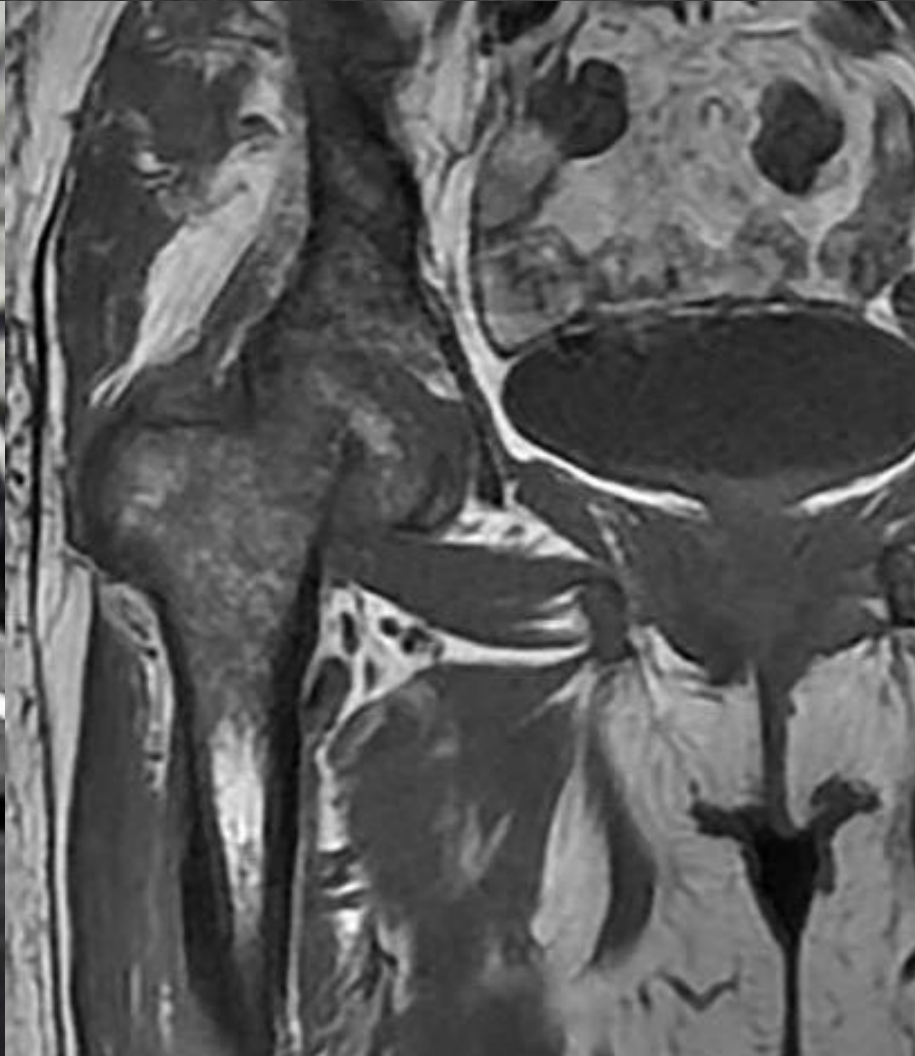

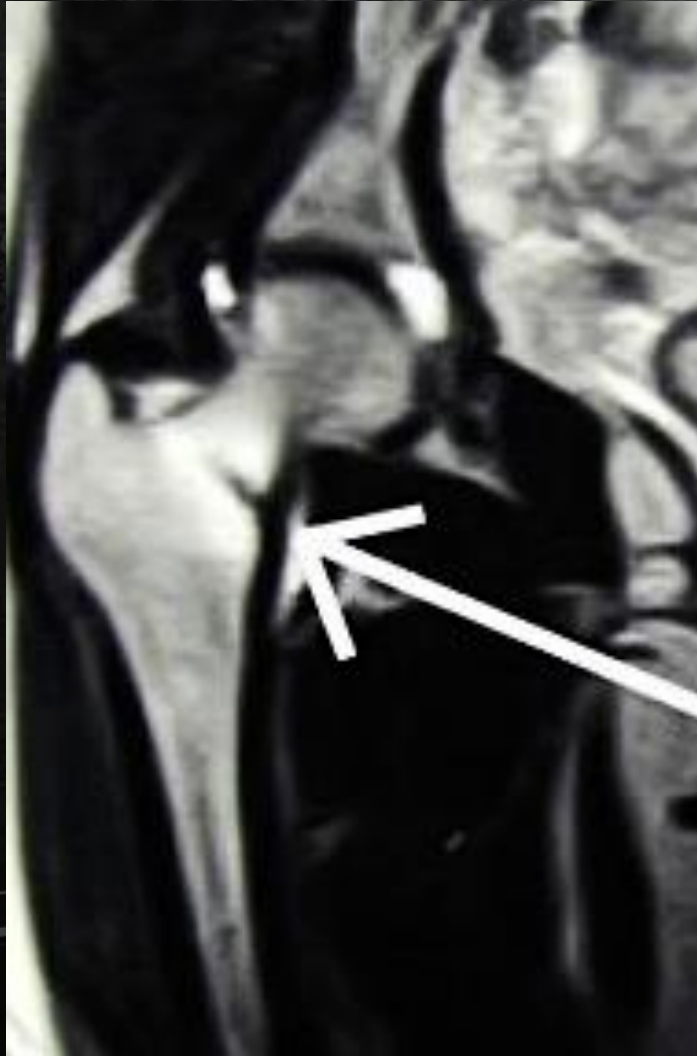
Investigations



Investigations

MRI



X - Ray

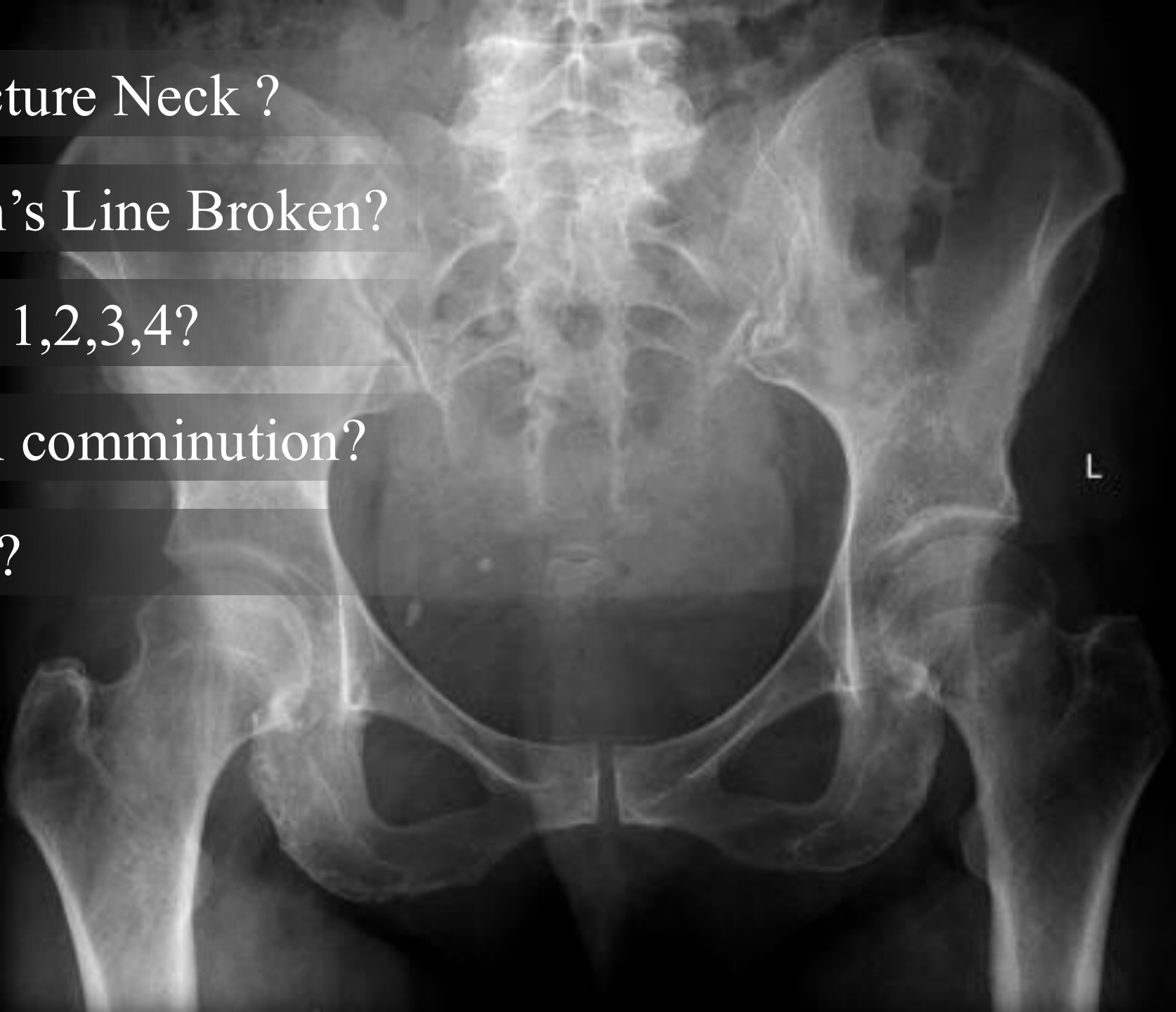
Is there a Fracture Neck ?

Is the Shenton's Line Broken?

Classification 1,2,3,4?

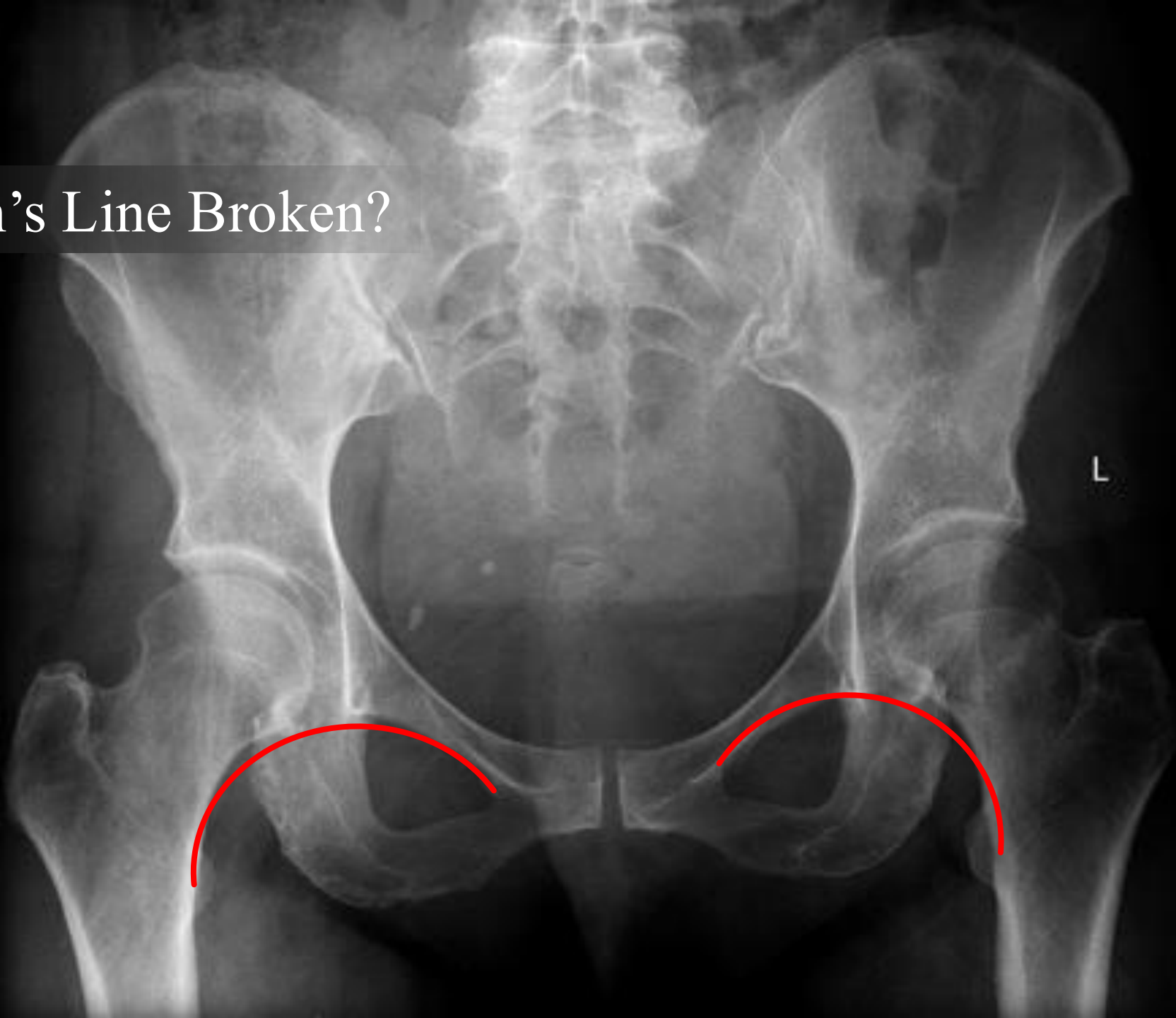
Posterior Wall comminution?

Singh's Index?



X - Ray

Is the Shenton's Line Broken?



Management

उपचार

Precarious Blood Supply

Difficult to maintain – Small fragment

High Complication Rates

Management

उपचार

Age

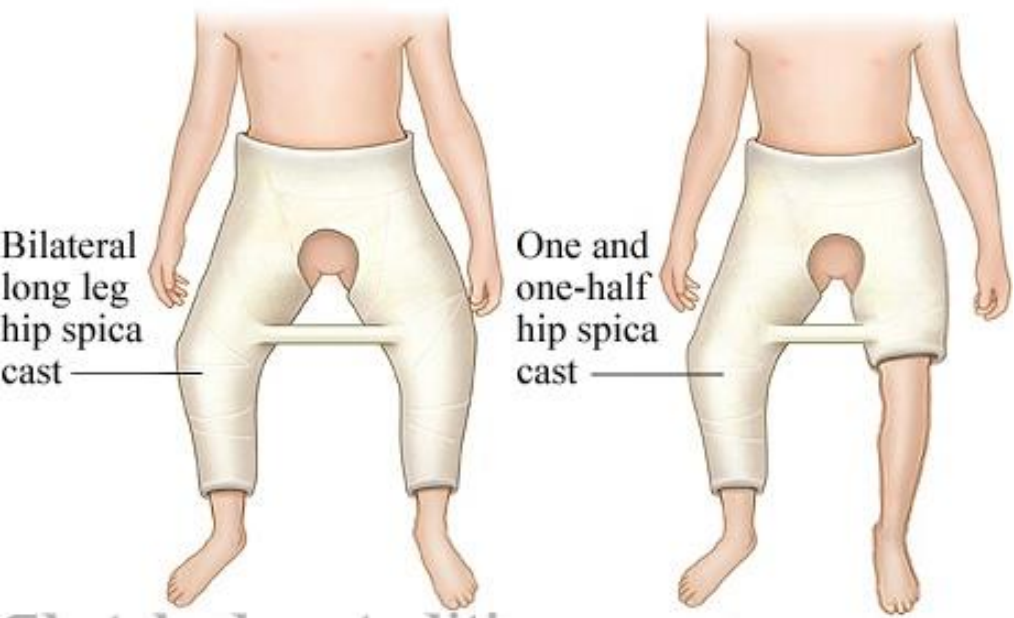Healing Potential

Quality of Bone

Functional Outcome

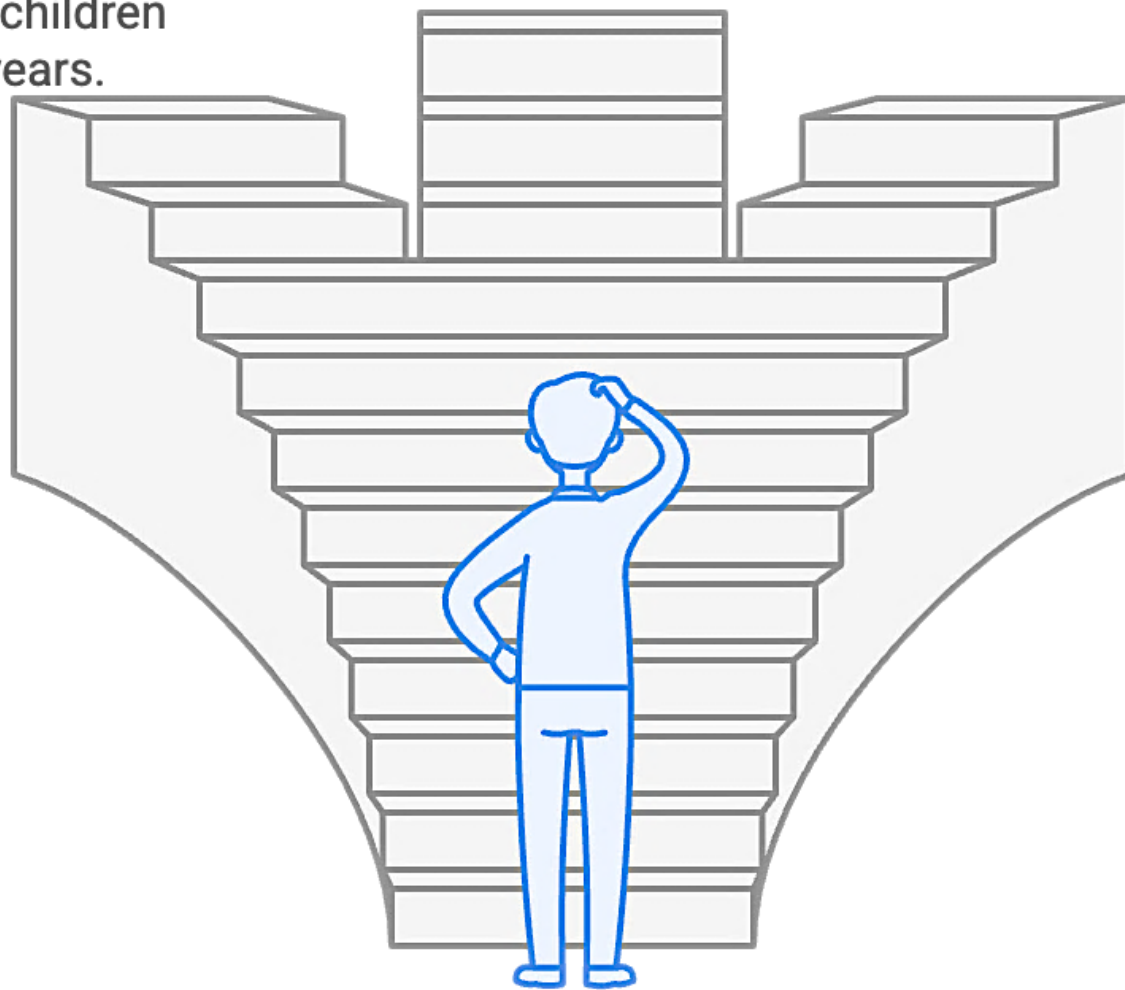
Spica Cast

Suitable for nondisplaced or minimally displaced fractures in children under 2 years.



Closed Reduction

Recommended for displaced fractures with epiphyseal involvement.



Open Reduction

Necessary if closed reduction is unsatisfactory.

Up to 2 Yr

Hip Spica
हिप स्पाइका




Open Reduction

Necessary if closed reduction is unsatisfactory.

What fixation method should be used for pediatric patients?

Cannulated Screws

Suitable for older children to ensure stable fixation.



Smooth Pins

Minimizes risk of premature physeal closure in very young children.



Moore's Pin

मूर पिन

Knowles Pin

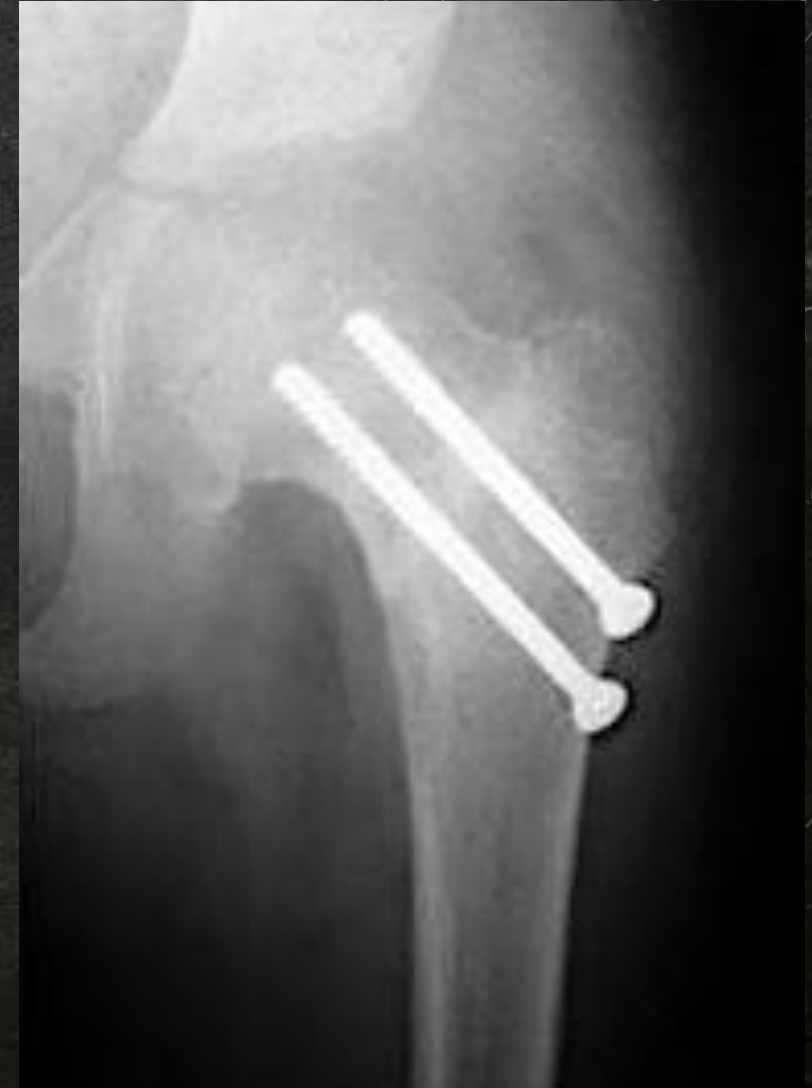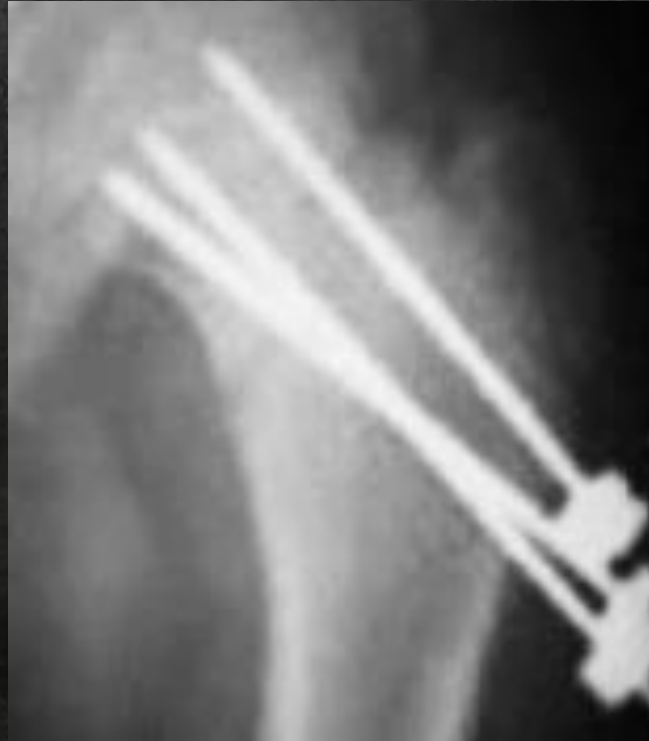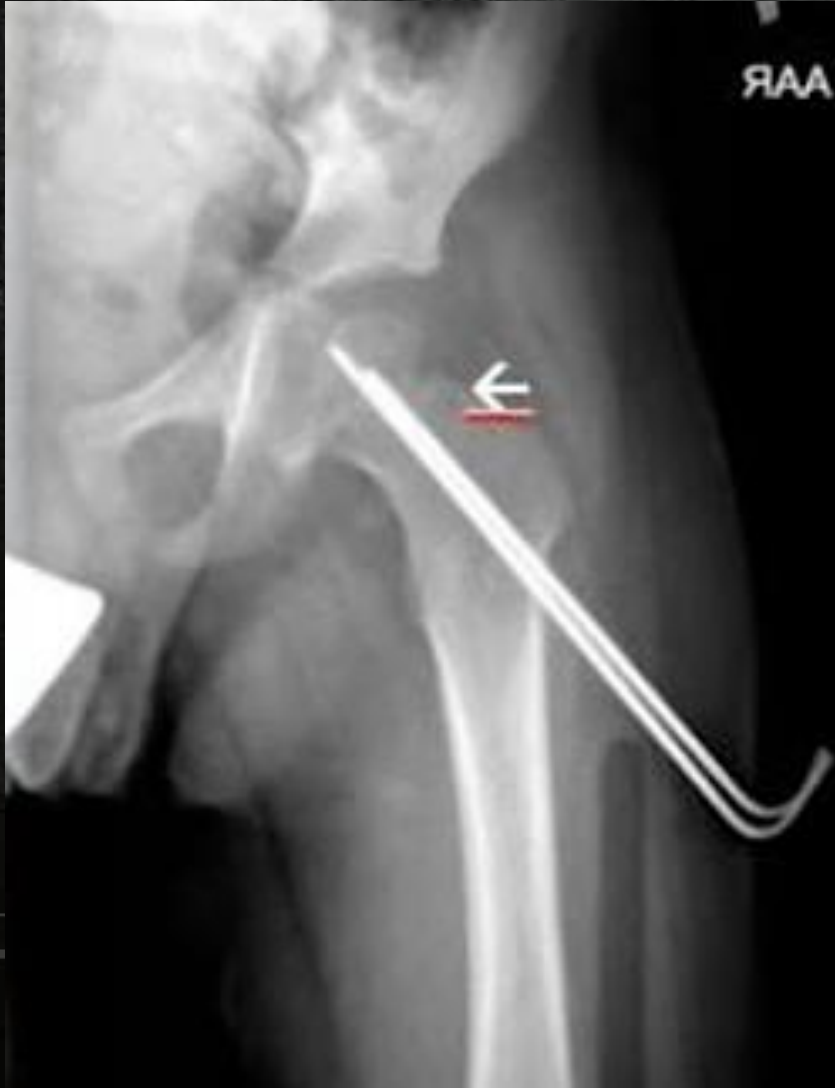नॉवेल पिन



Cannulated Cancellous Screw

कैन्युलेटेड कैंसलस स्क्रू

Children



Adult



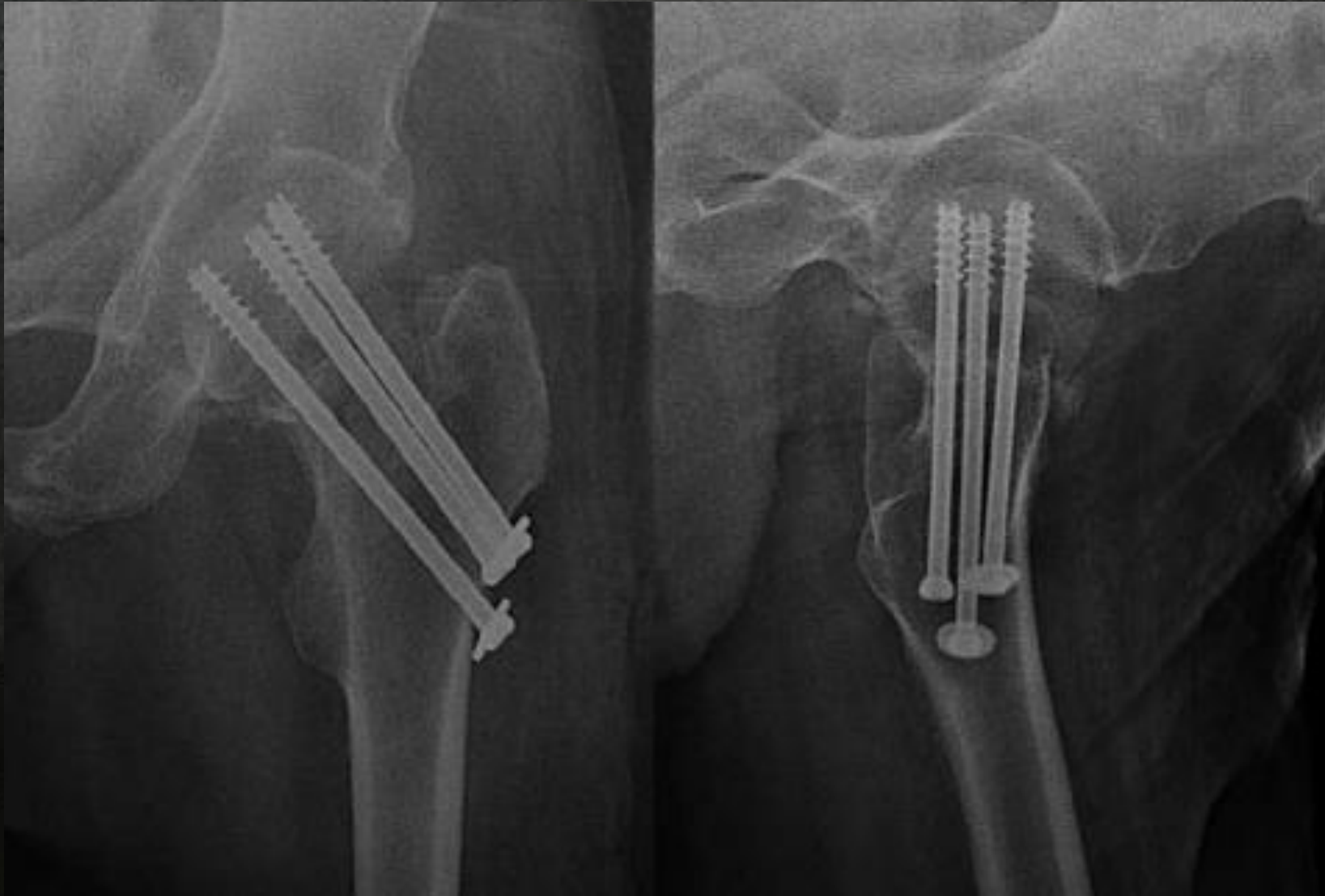
Anatomical Reduction

Absolute Stability

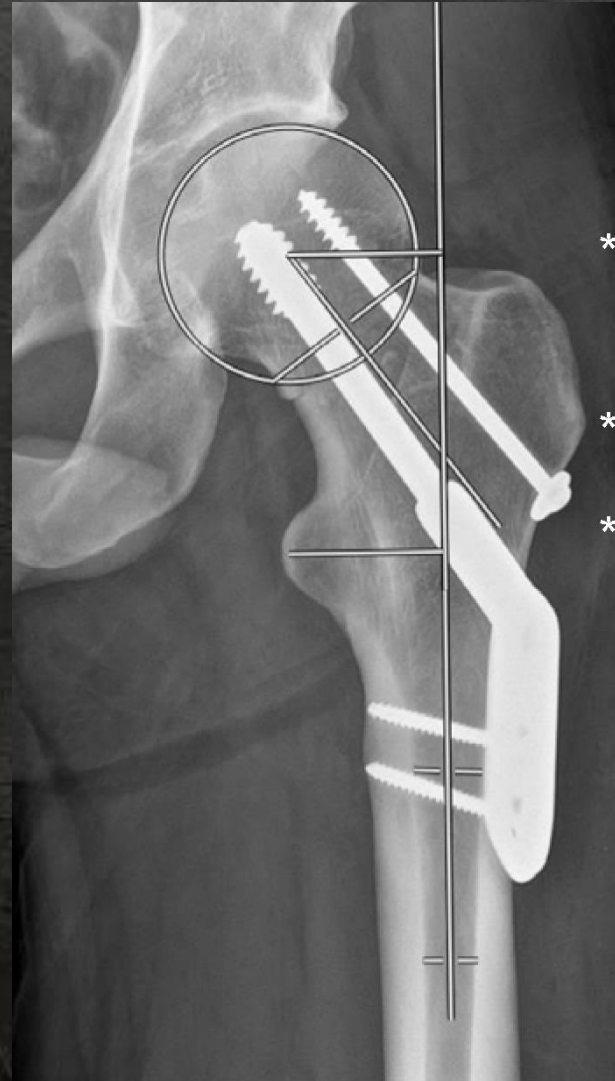
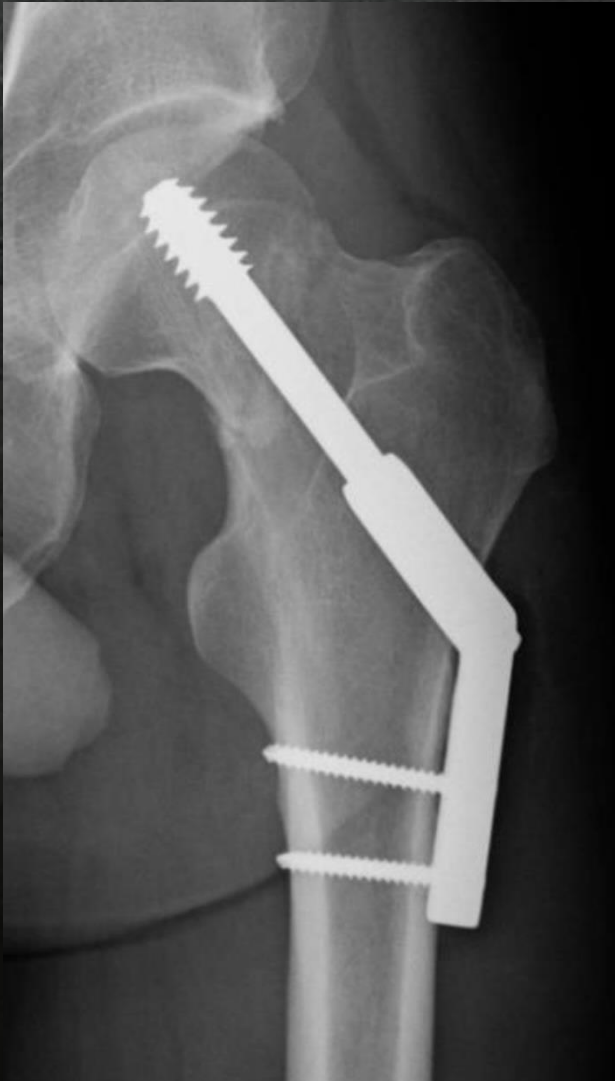Preservation of Blood Supply

Early Mobilization

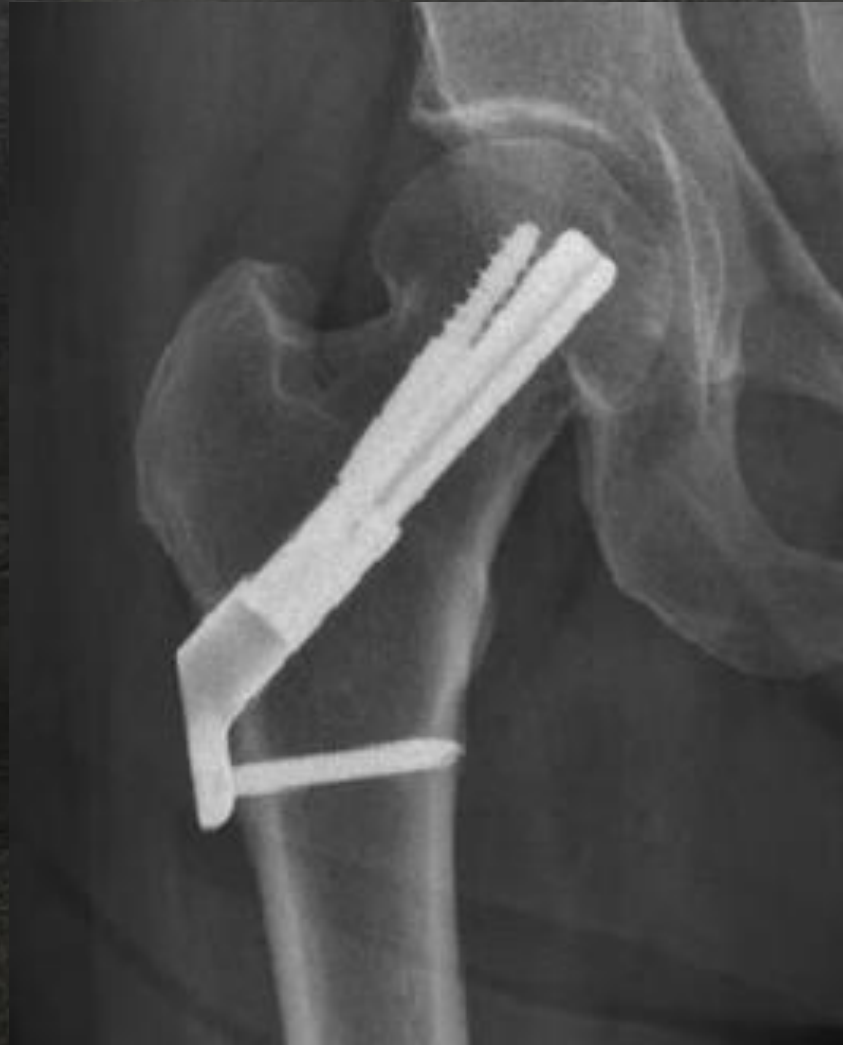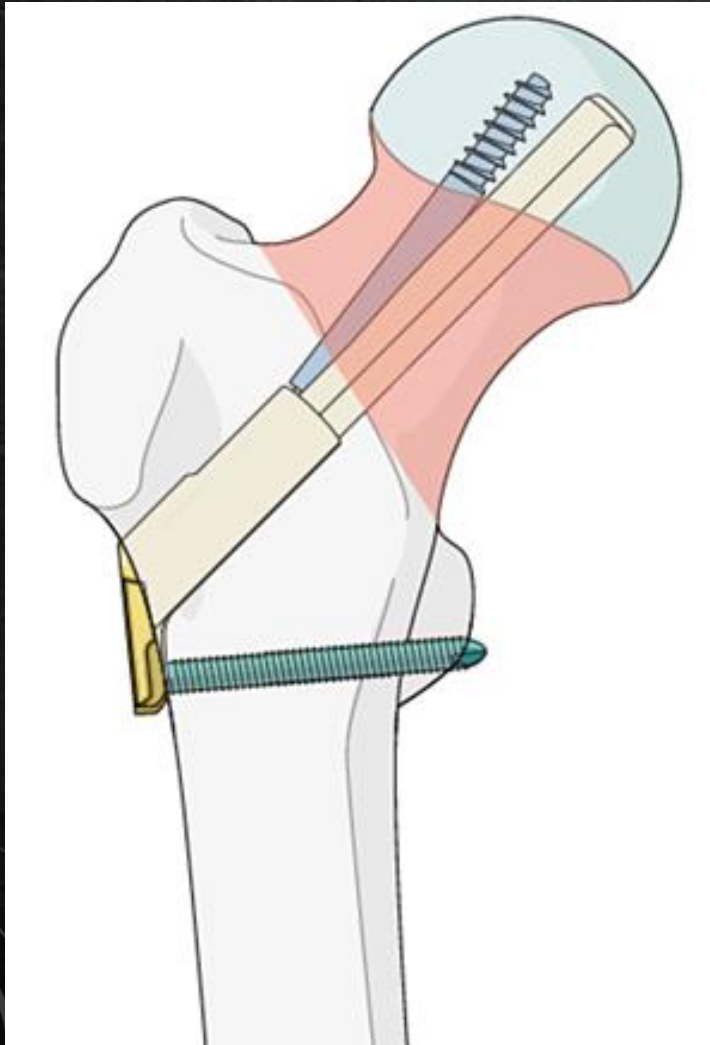
Cannulated Cancellous Screw



Dynamic Hip Screw (DHS)



Femoral Neck System (FNS)



Cannulated Cancellous Screw

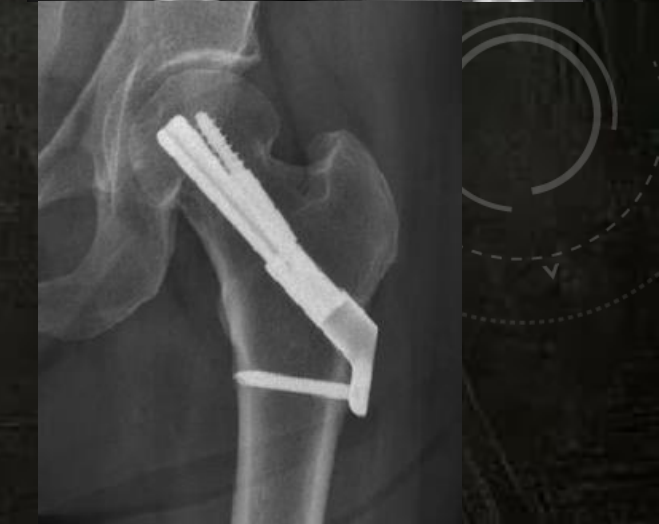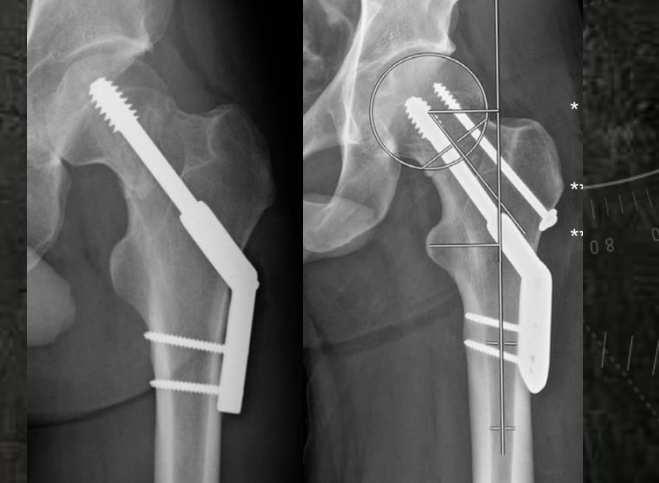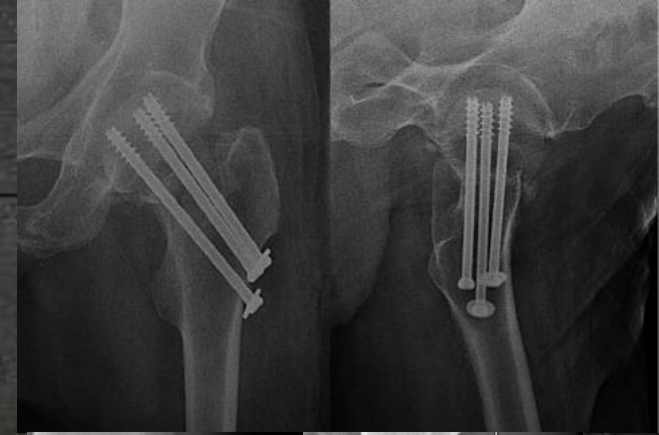
कैन्युलेटेड कैंसलस स्क्रू

Dynamic Hip Screw (DHS)

डायनामिक हिप स्क्रू

Femoral Neck System (FNS)

फ़ीमोरल नेक सिस्टम



Osteosynthesis

VS

Replacement

Osteosynthesis

Age

Healing Potential

Quality of Bone

Functional Outcome

Replacement

Old Age

> 65

Replacement



Chronological Age



Number of years lived



Cannot be changed

VS



Biological Age



Reflects how well your body functions




Influenced by lifestyle and habits

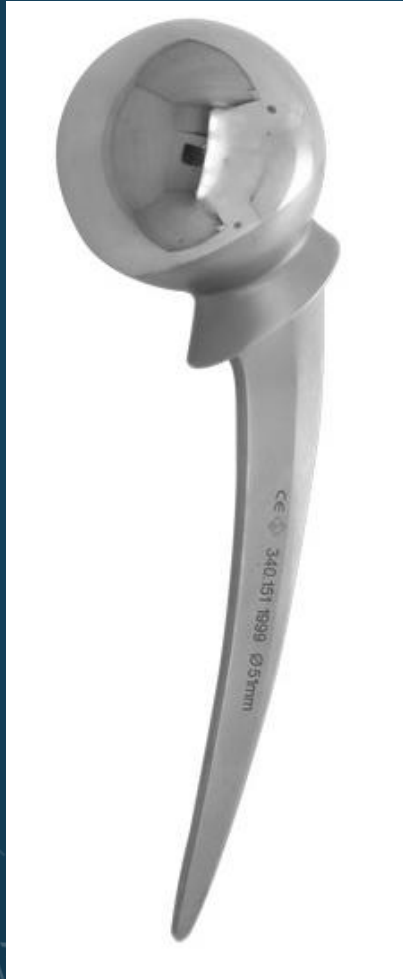Old Age

> 65

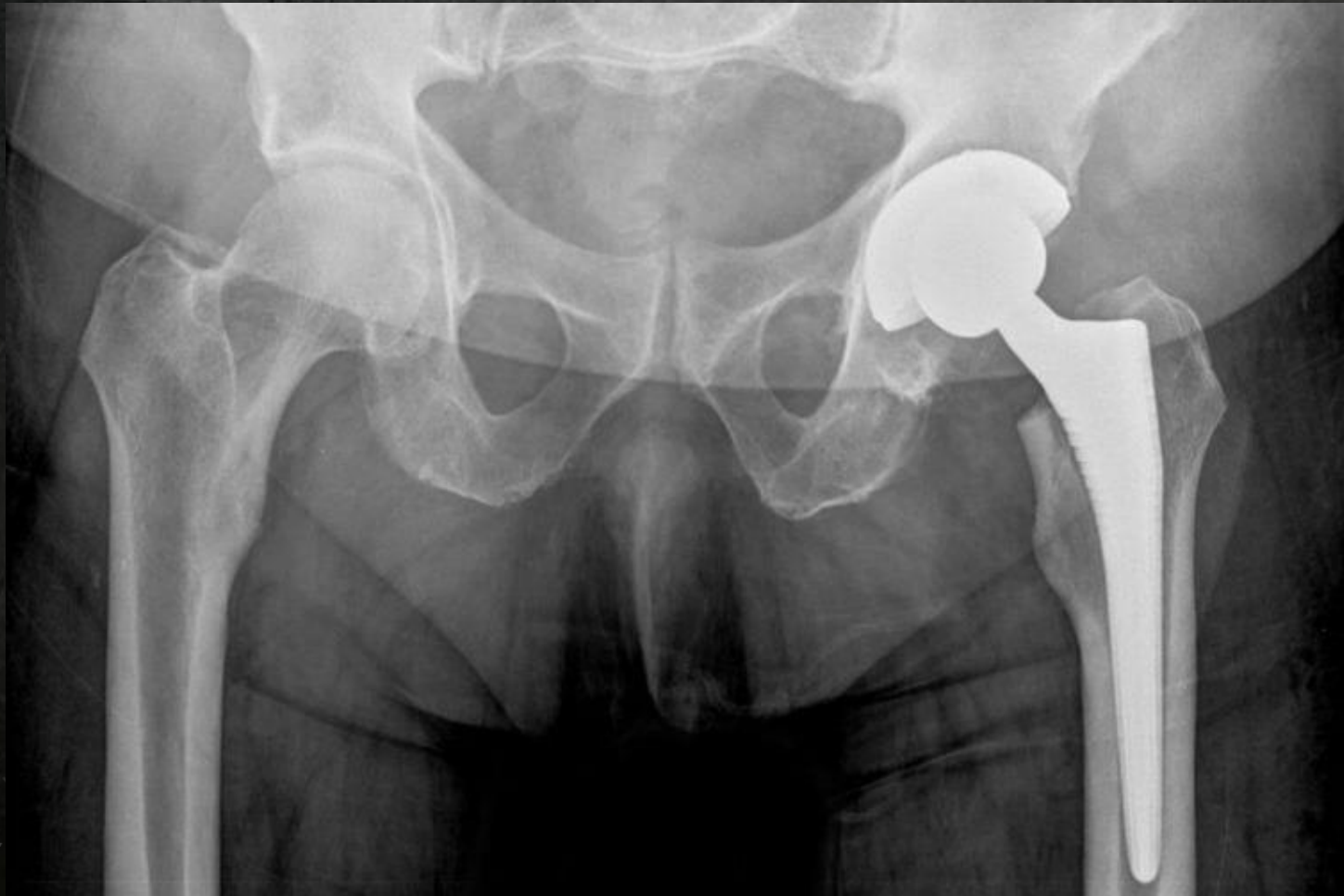Replacement



Hemi Arthroplasty



Total Hip Arthroplasty



Complications

Non Union

AVN

OA

Non Union

Non Union

9

3

M
O
N
T
H

Non Union

| Hematoma

| Pressure Effect

| Blood Supply

| Periosteum

Non Union

| Type of #

| Posterior wall comm.

| Inaccurate Reduction

| Inadequate Fixation

Pain ?



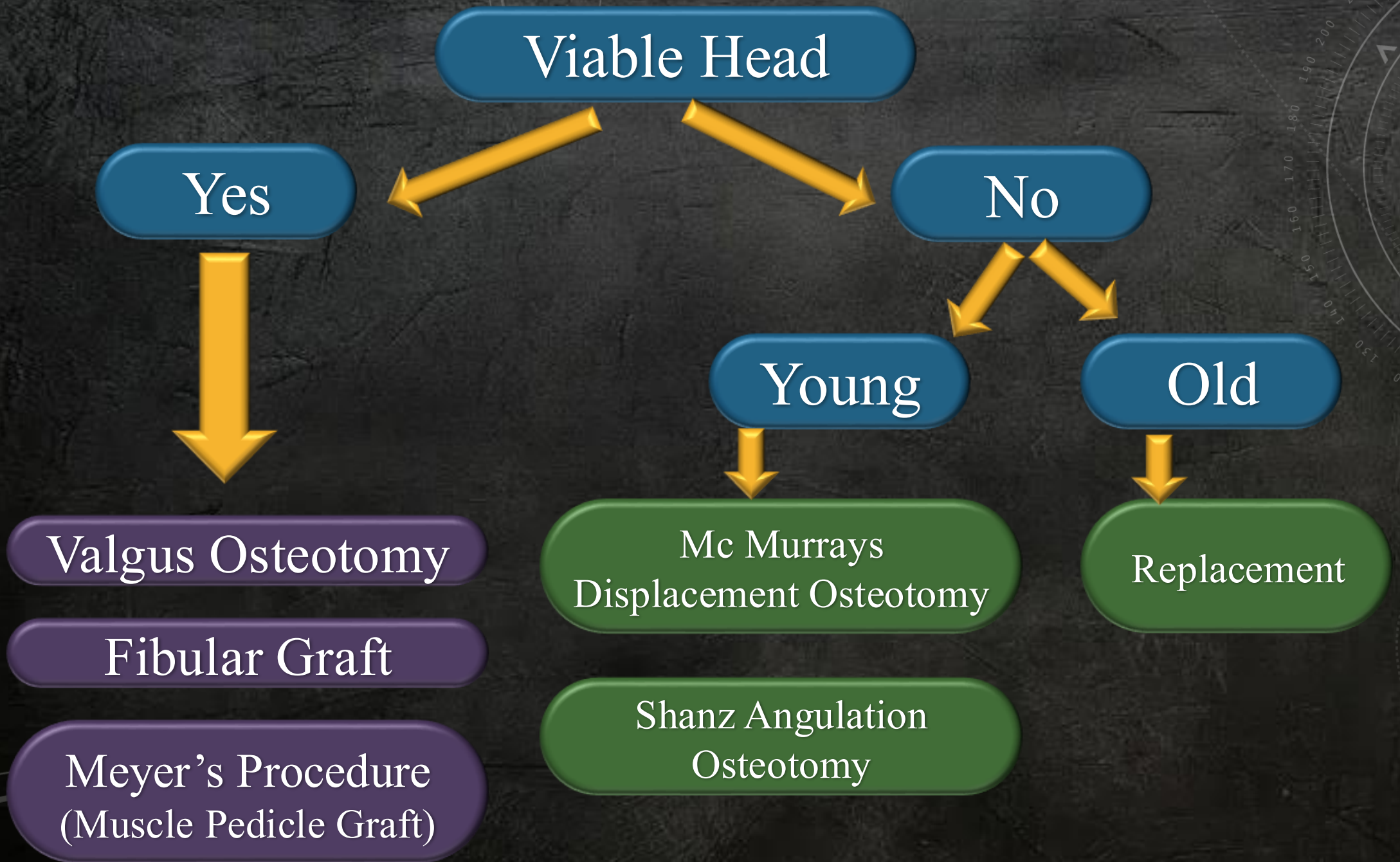
Unable to bear weight

Wasting

Shortening of limb

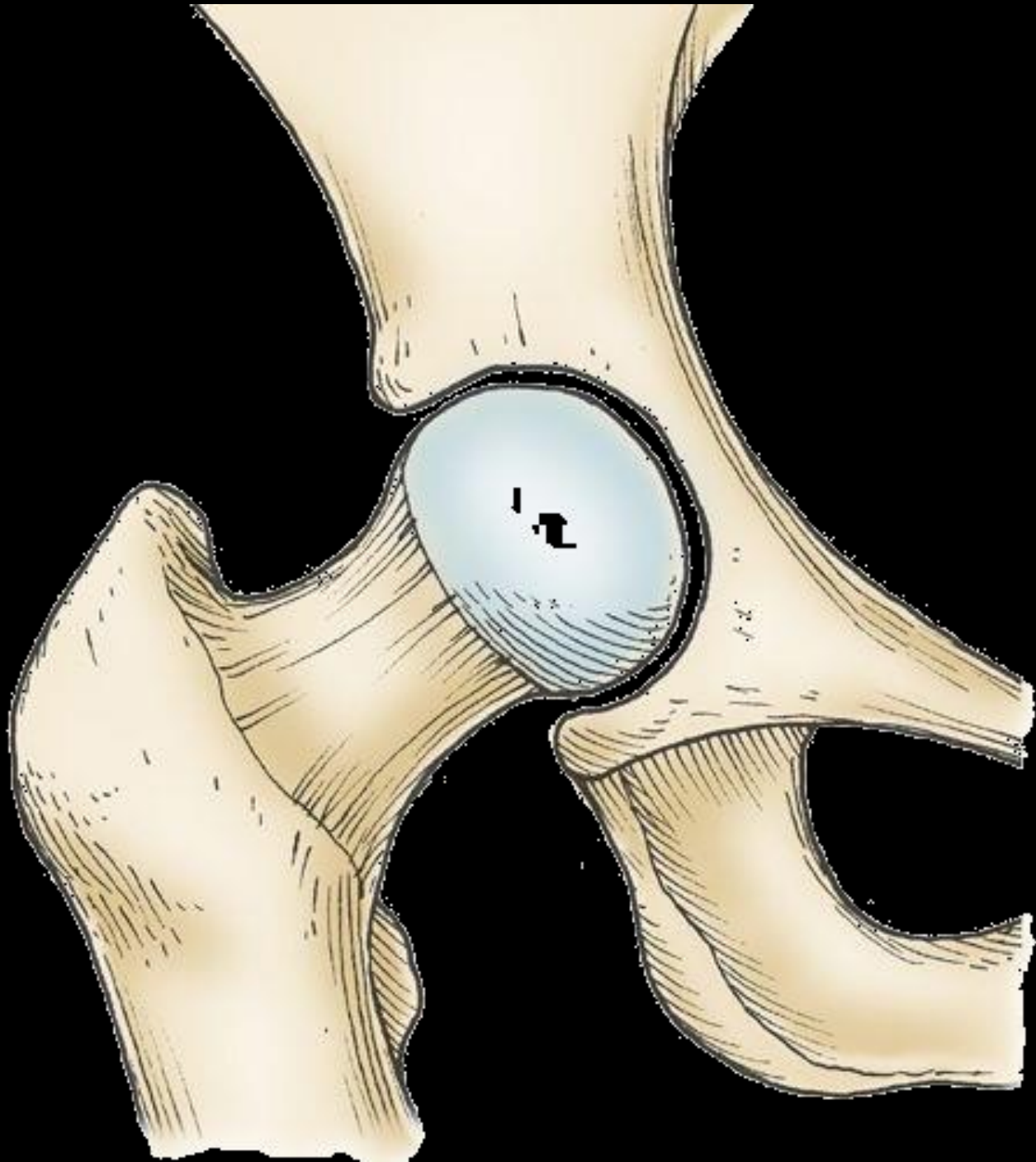
Clinical

Treatment

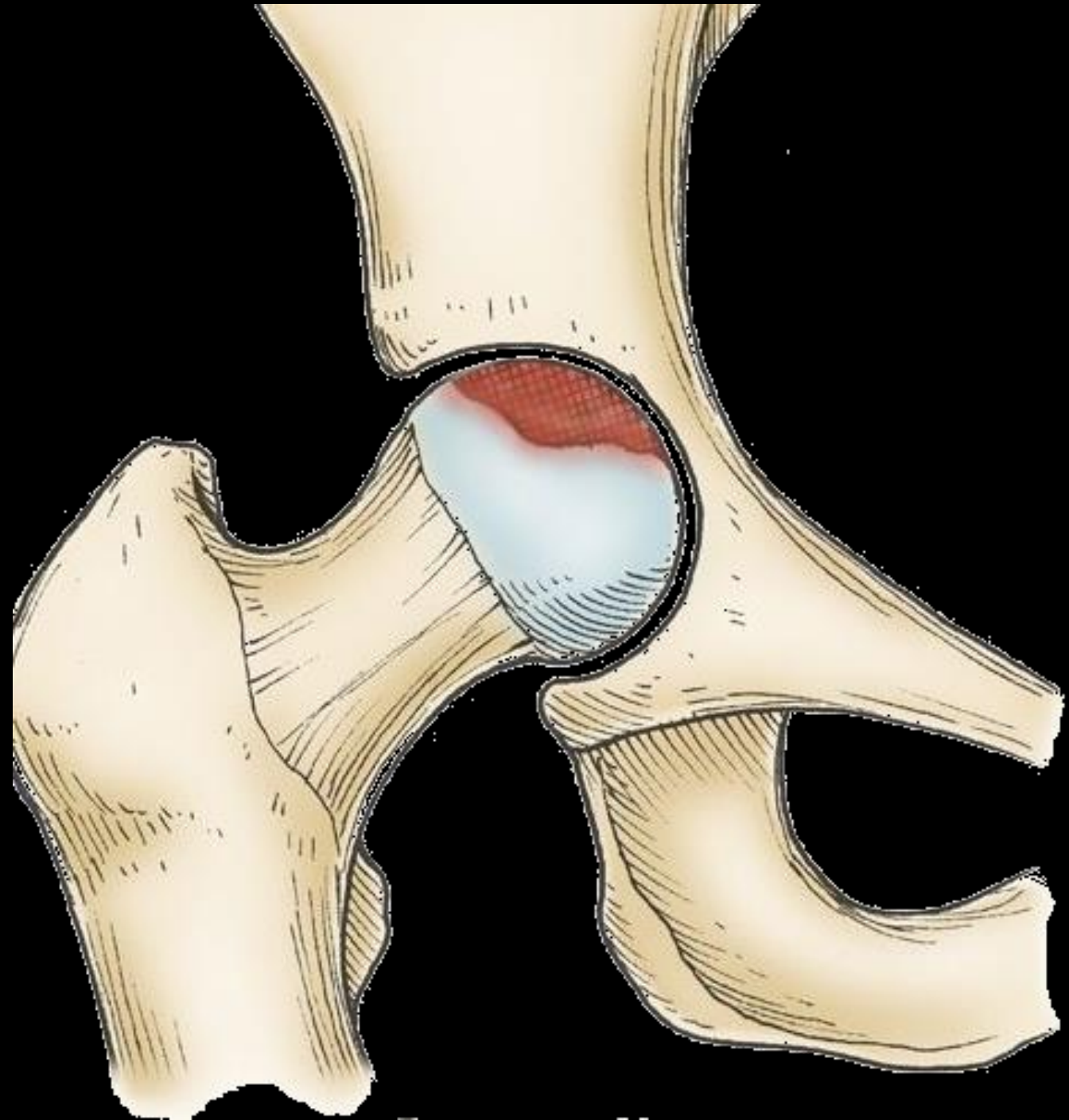


AVN

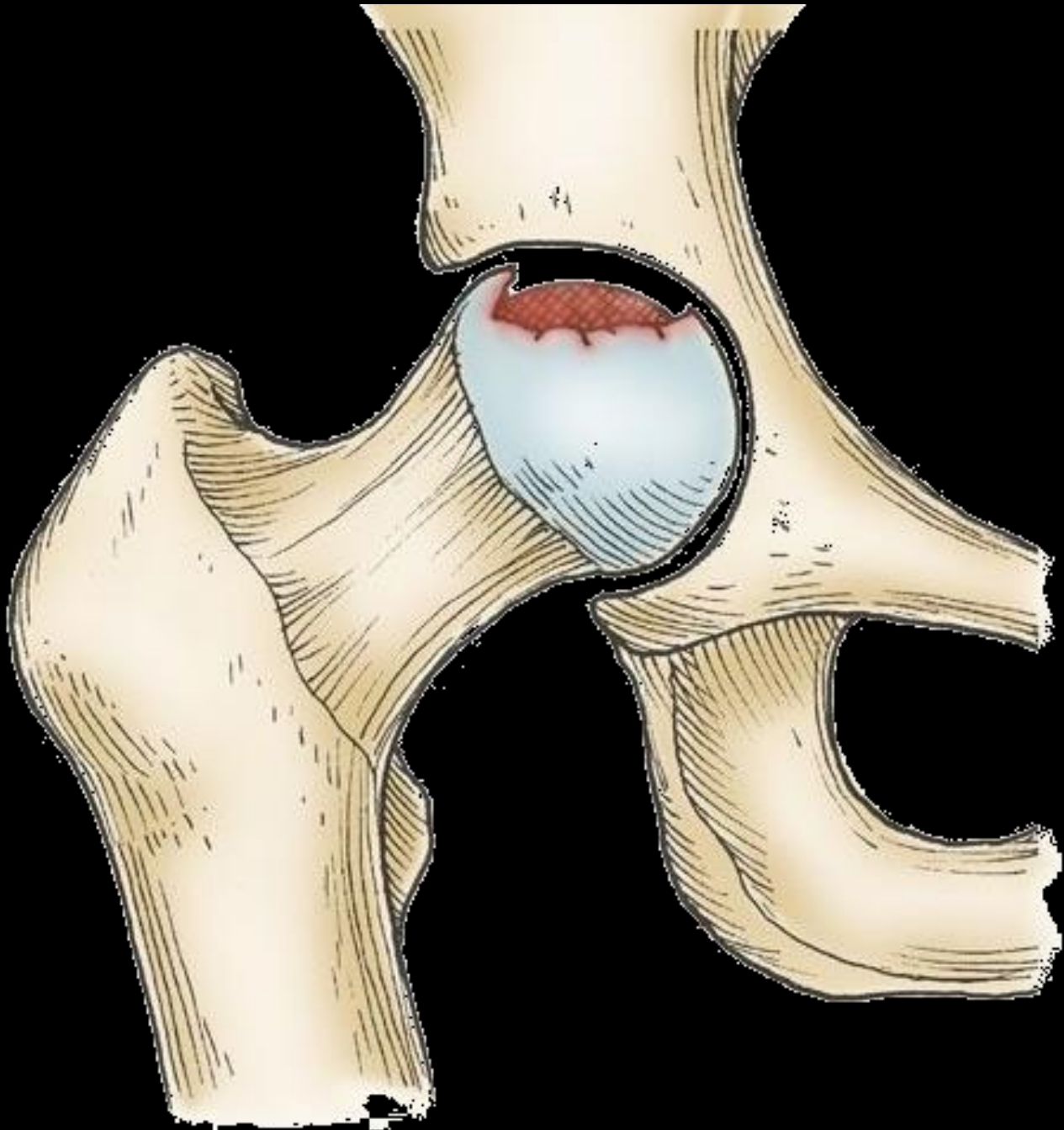
AVN



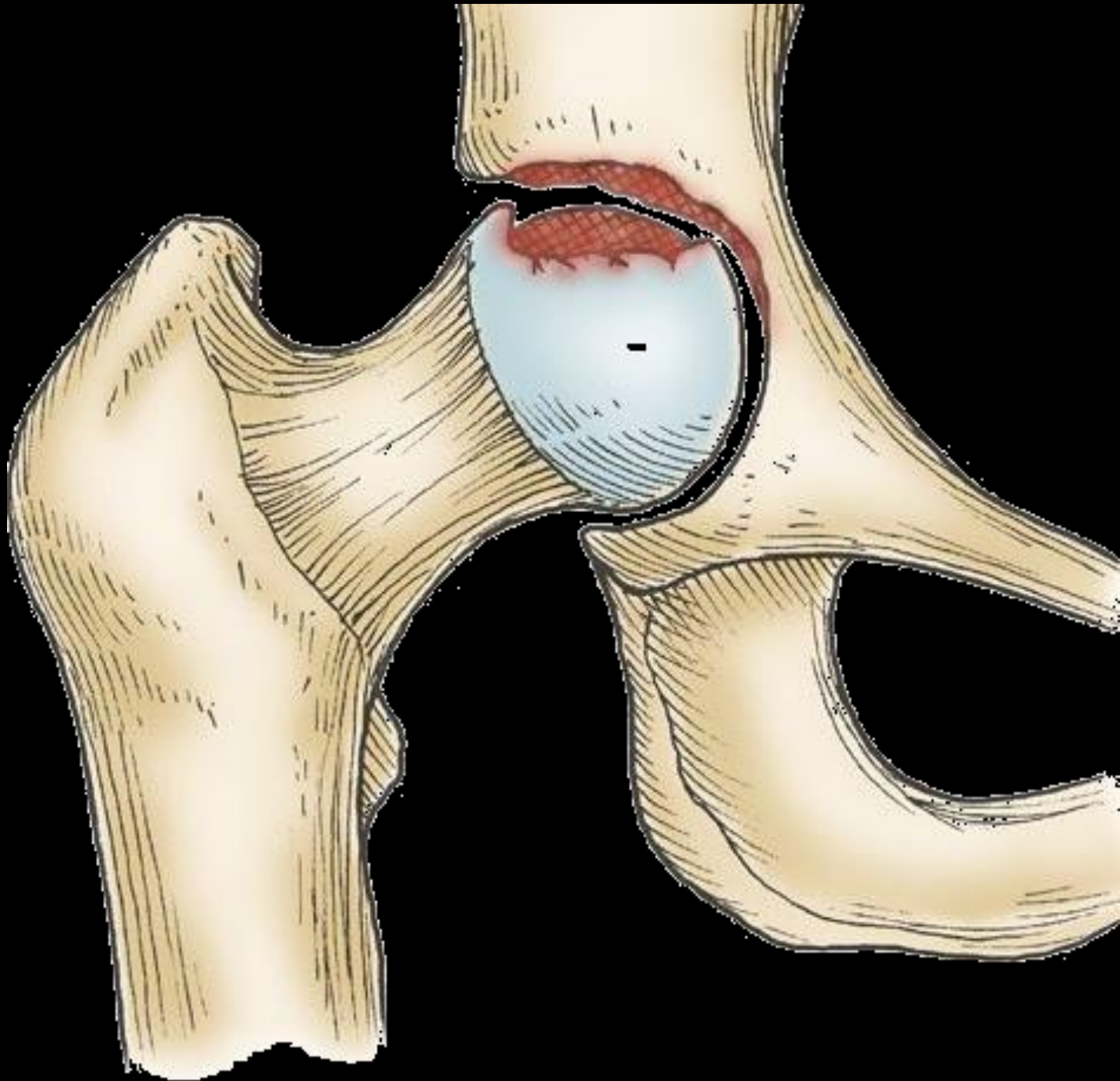
AVN



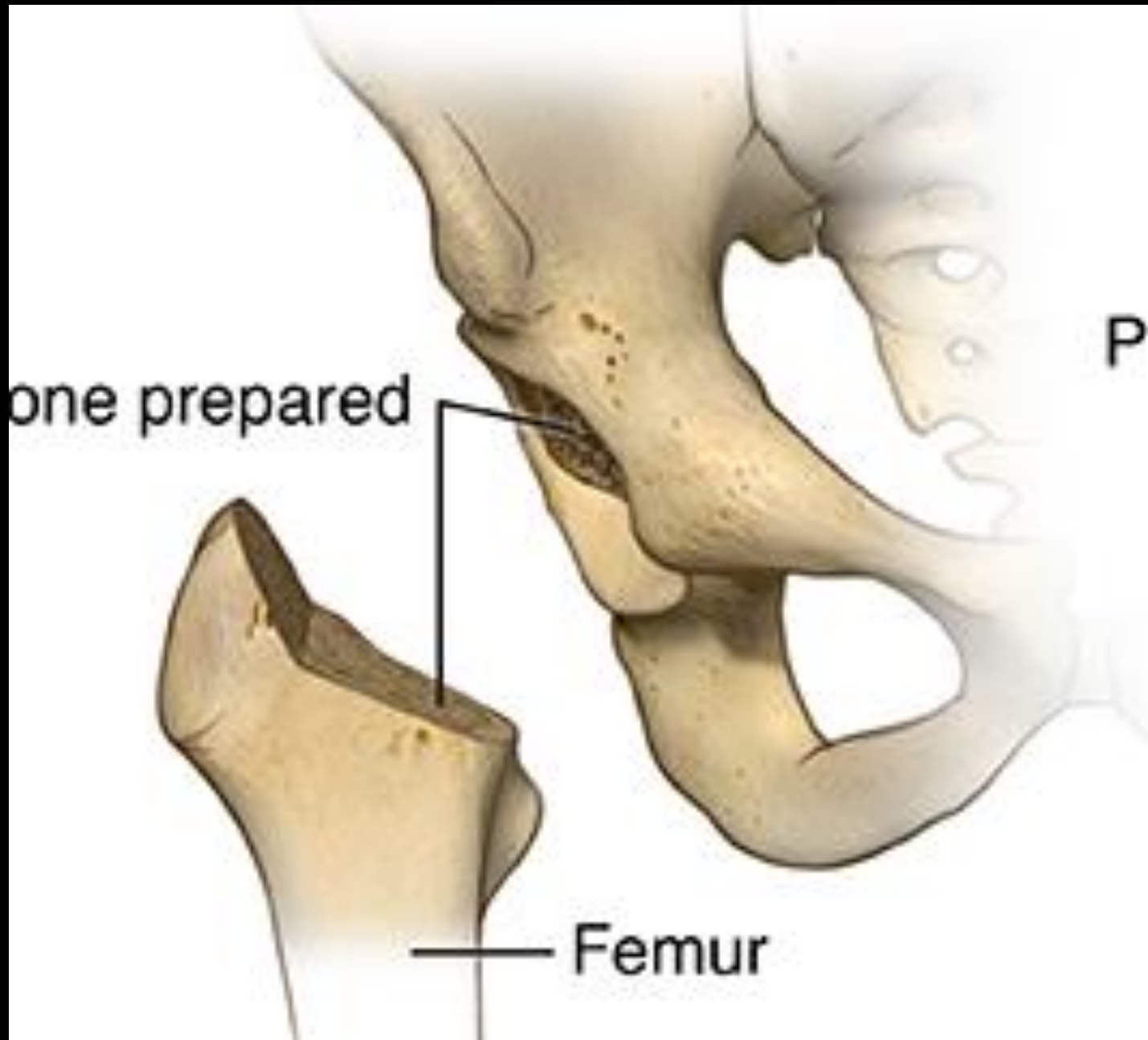AVN



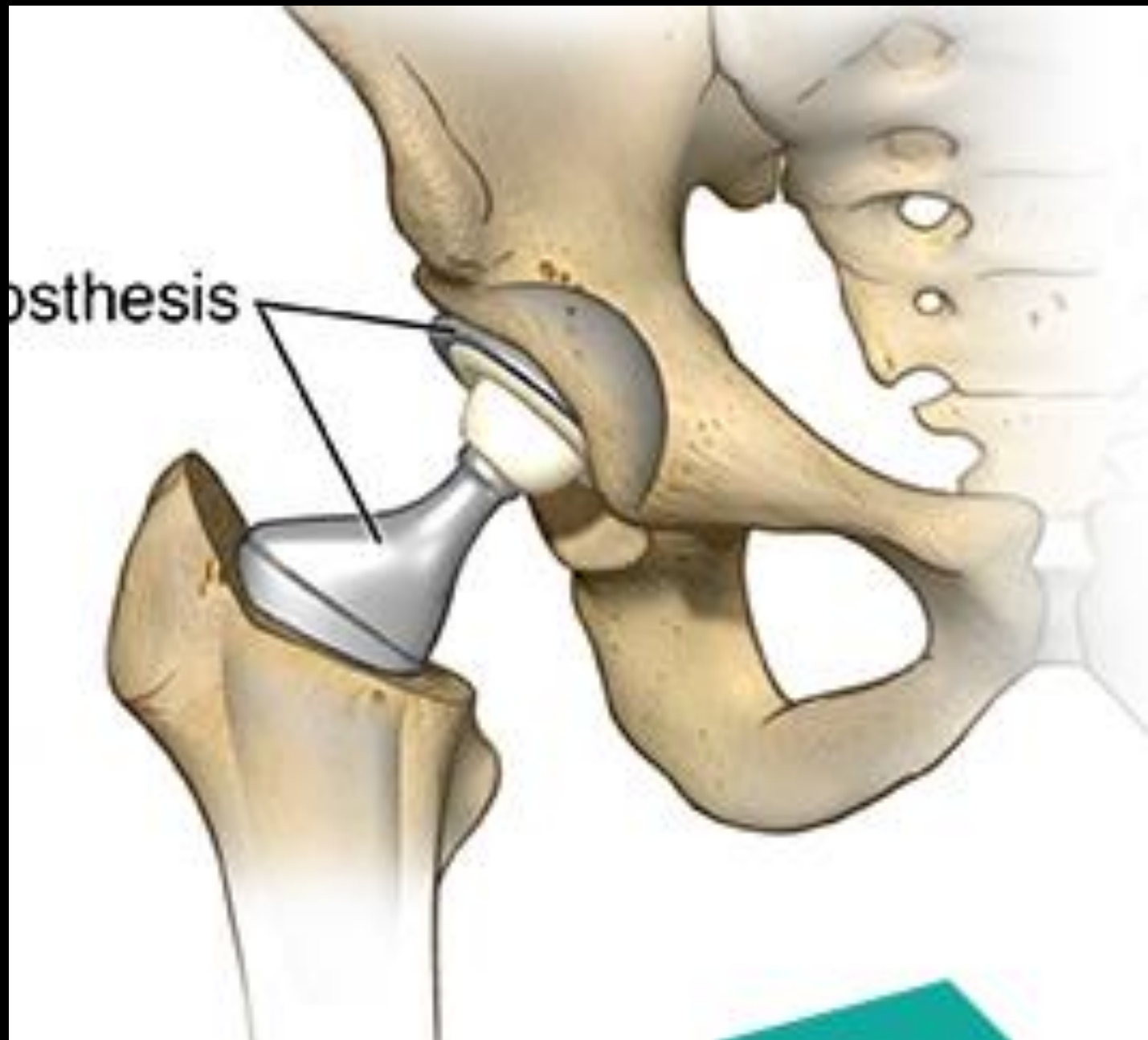AVN



AVN

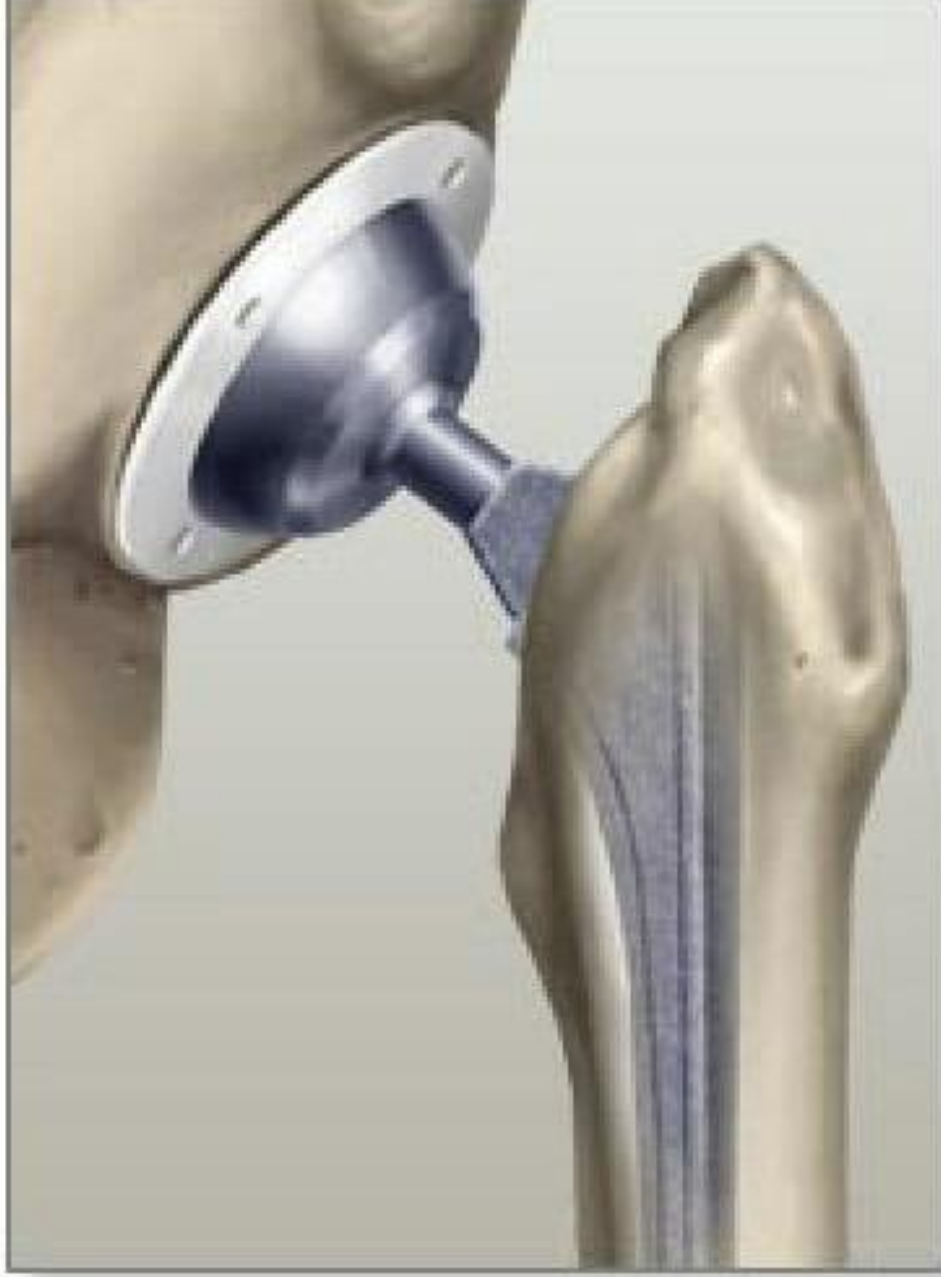
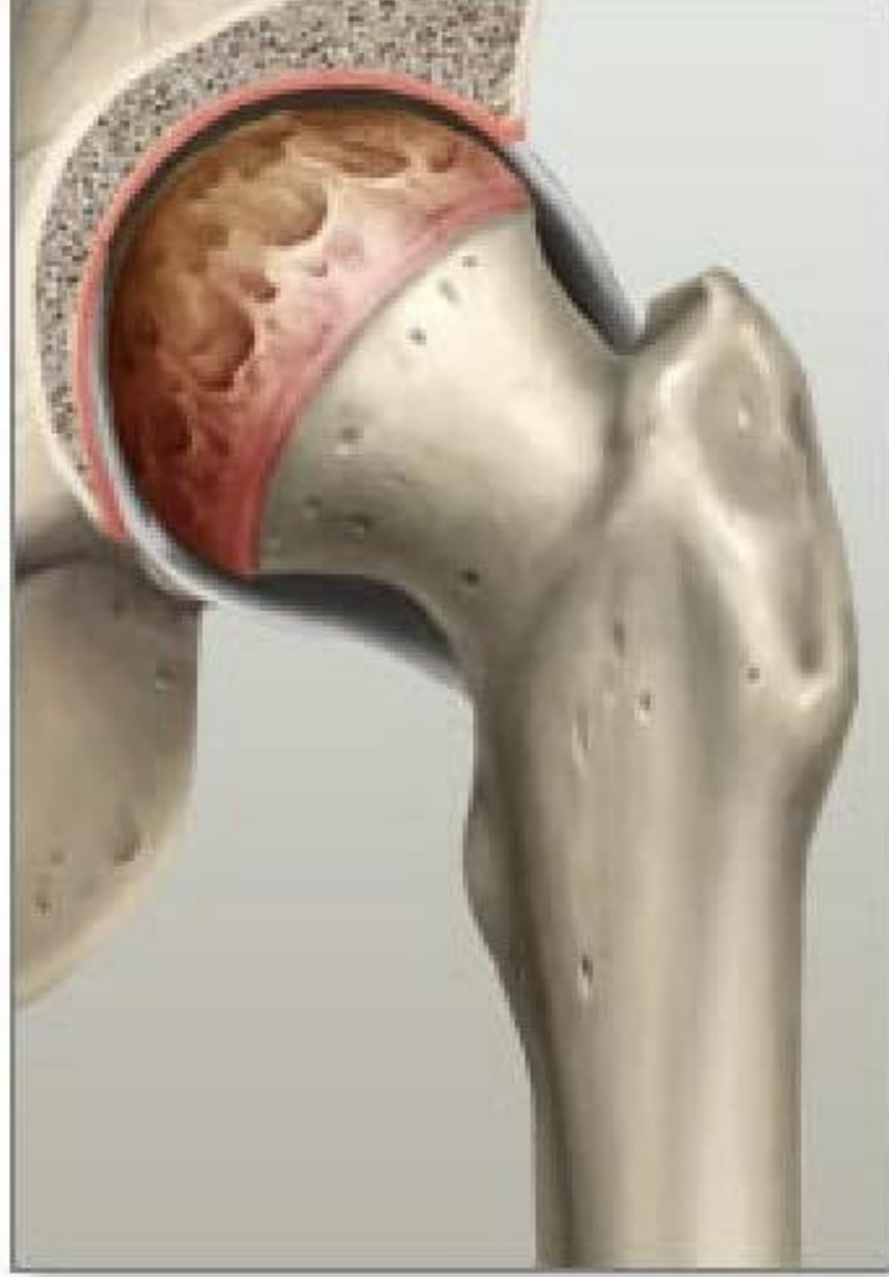
AVN

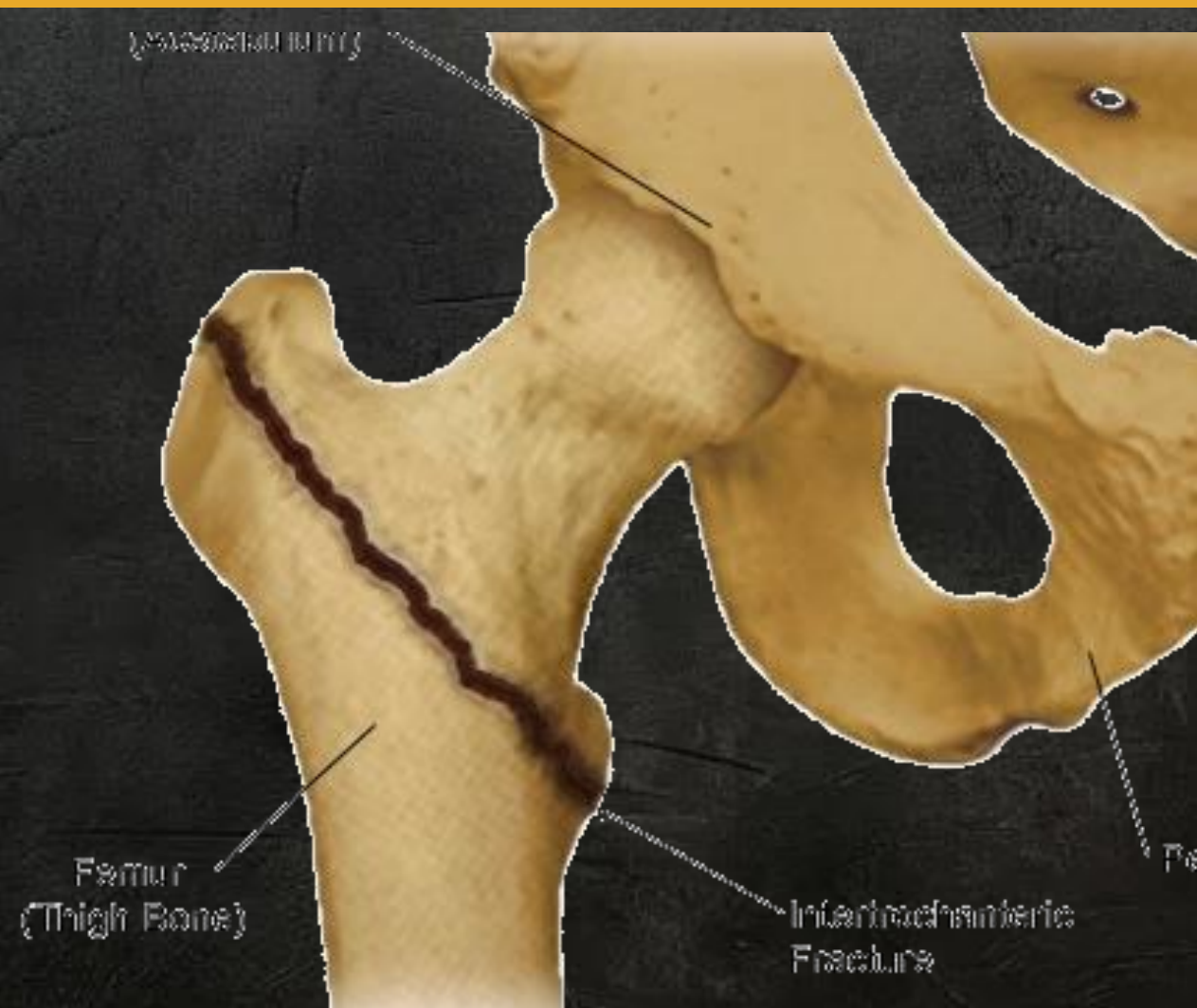

OA

OA



Intertrochanteric



Intertrochanteric

| Older age

| Tender GT

| Ext Rotation, Shortening

| Malunion

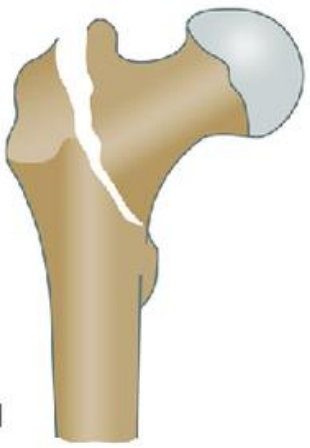| Evans Classification

| Boyd & Griffin

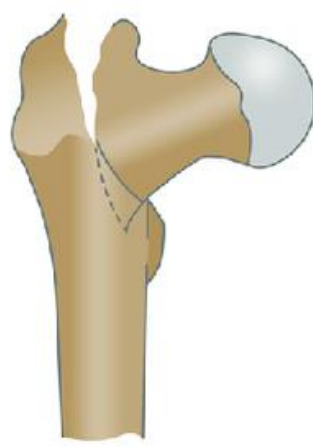
| AO Classification

Intertrochanteric

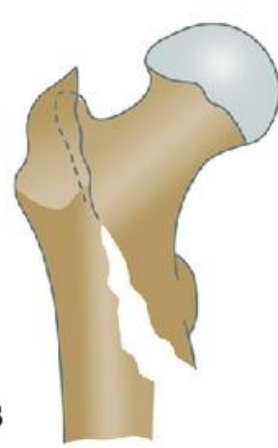A1.1



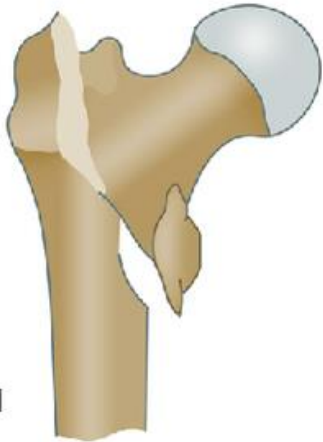A1.2



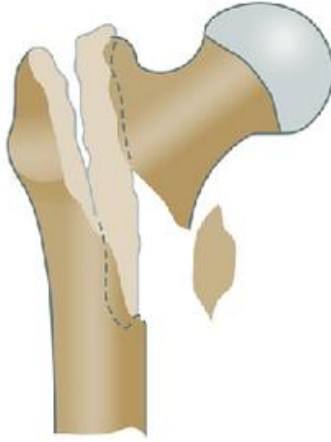A1.3



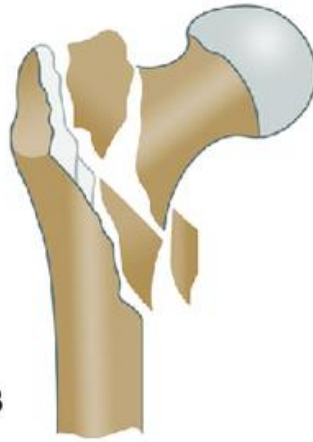A2.1



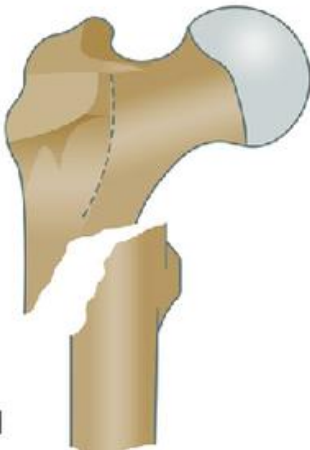A2.2



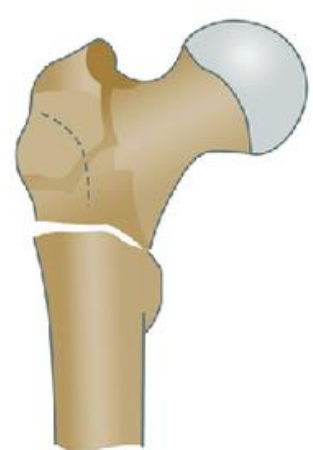
A2.3



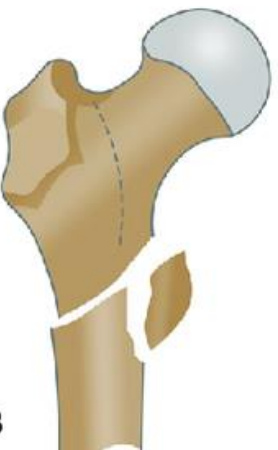
A3.1



A3.2

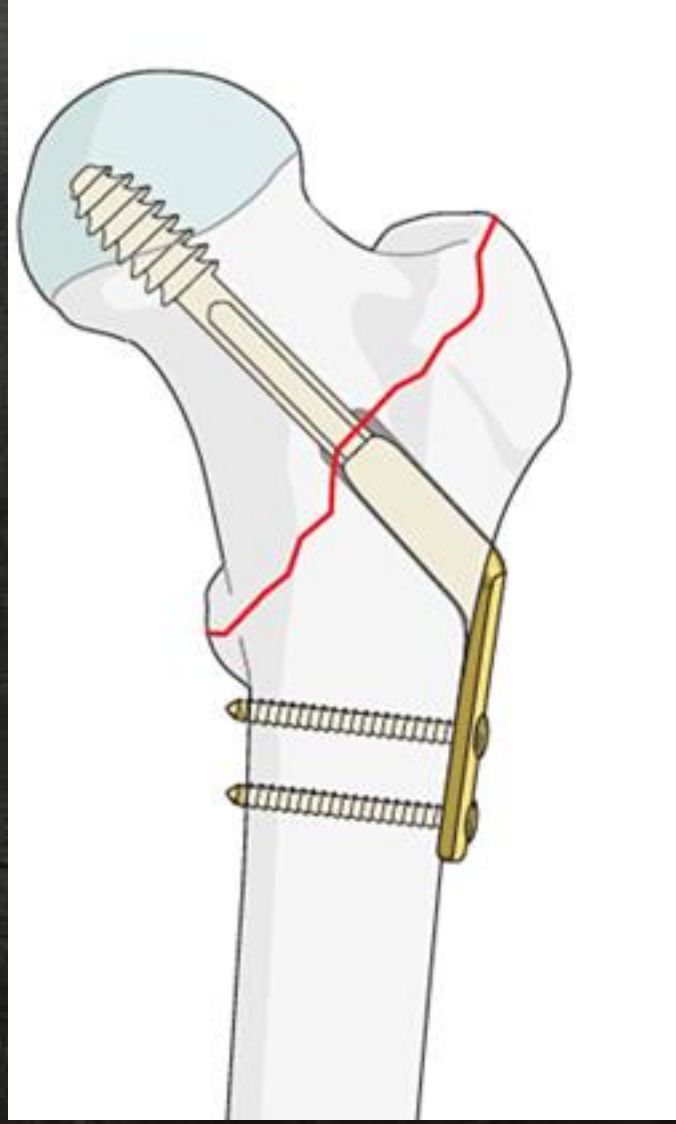


A3.3



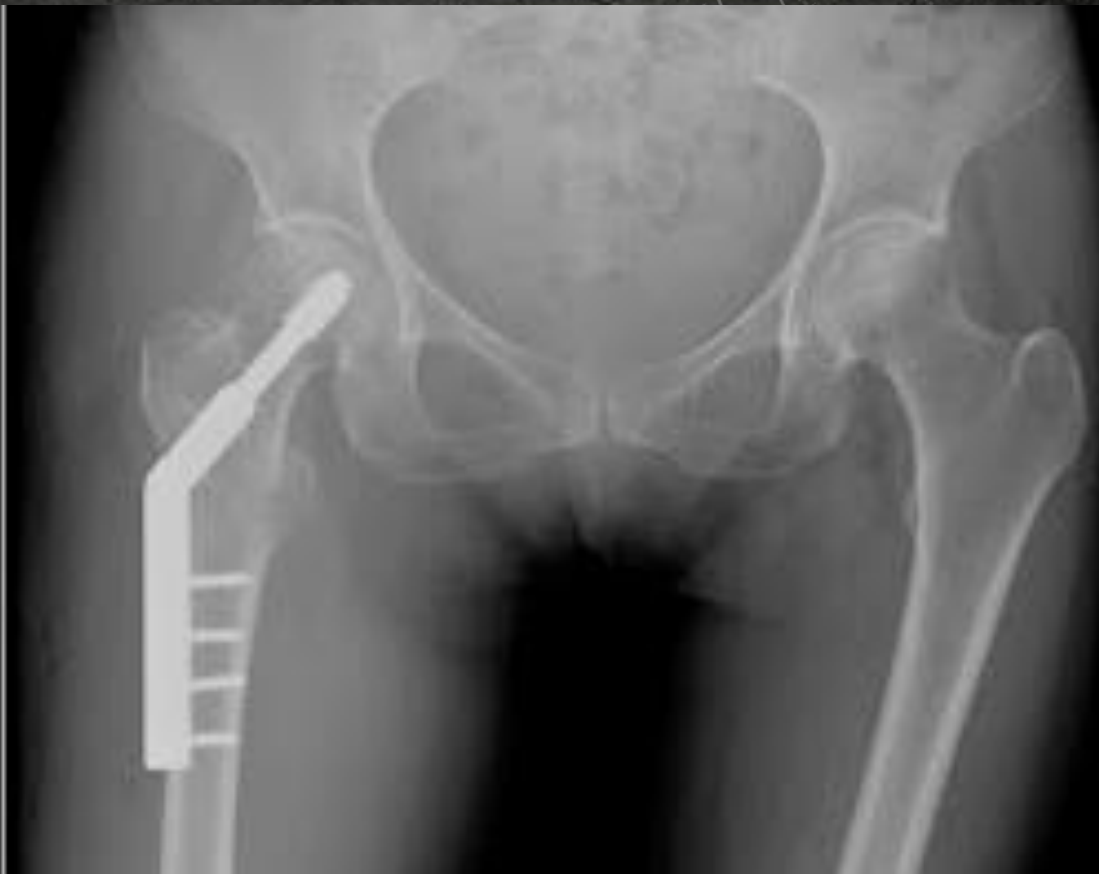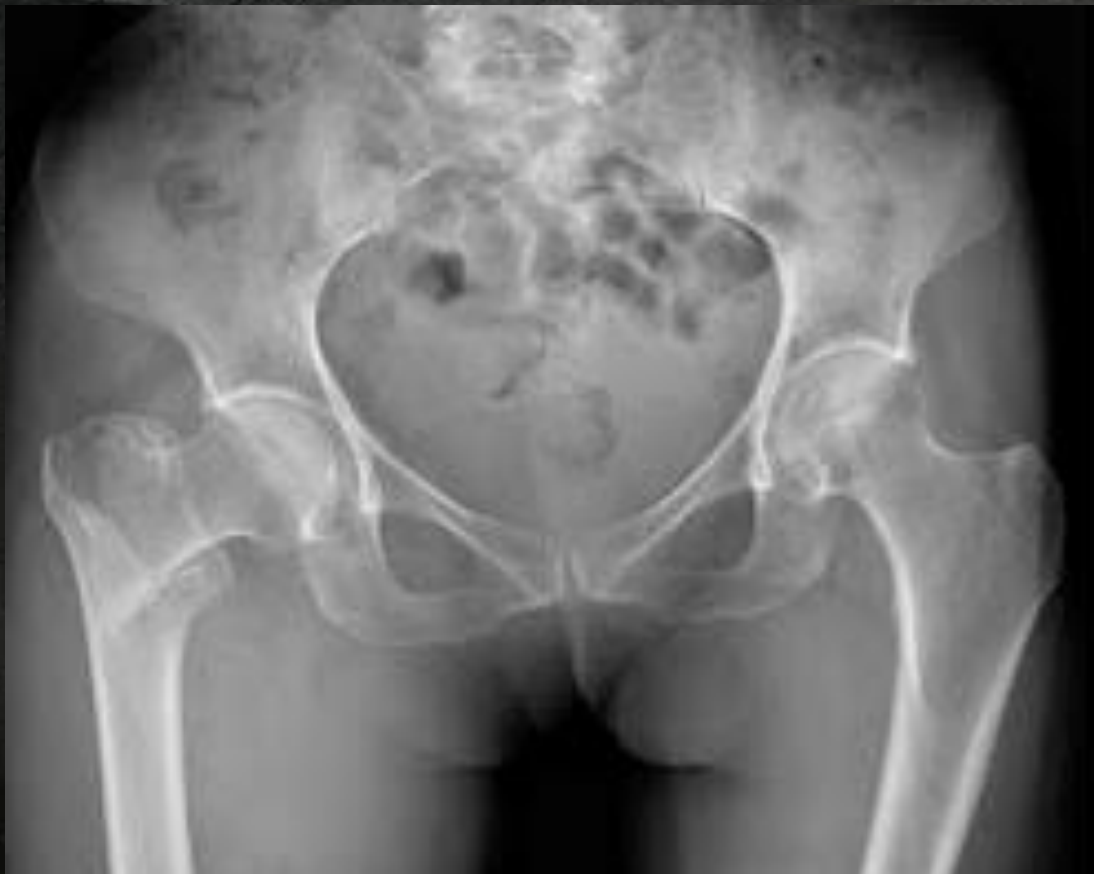Intertrochanteric

DHS



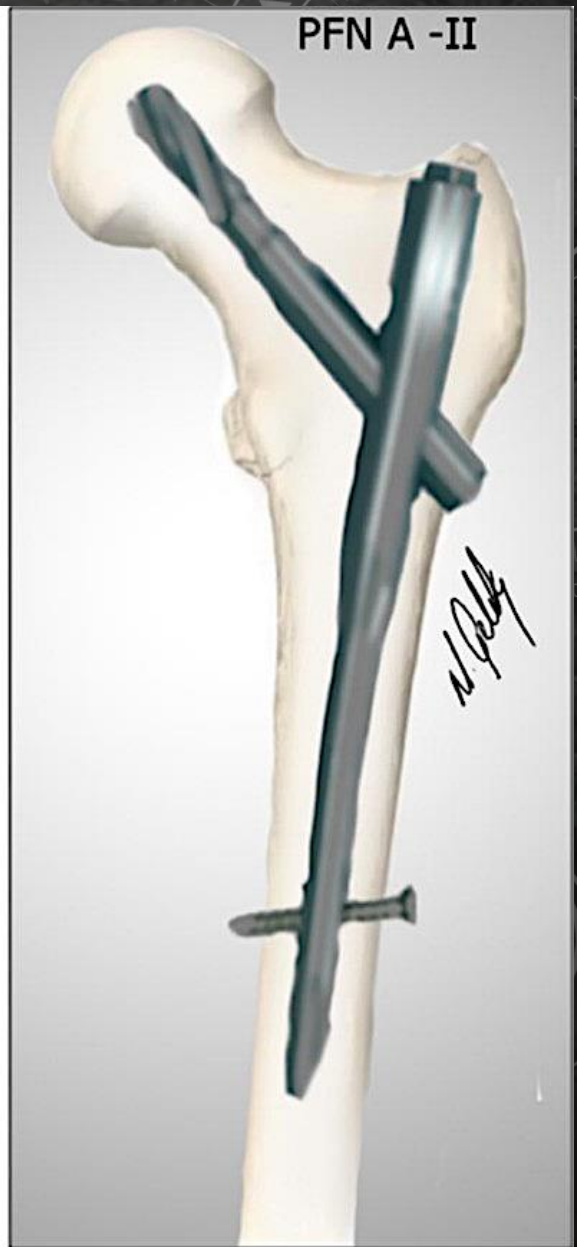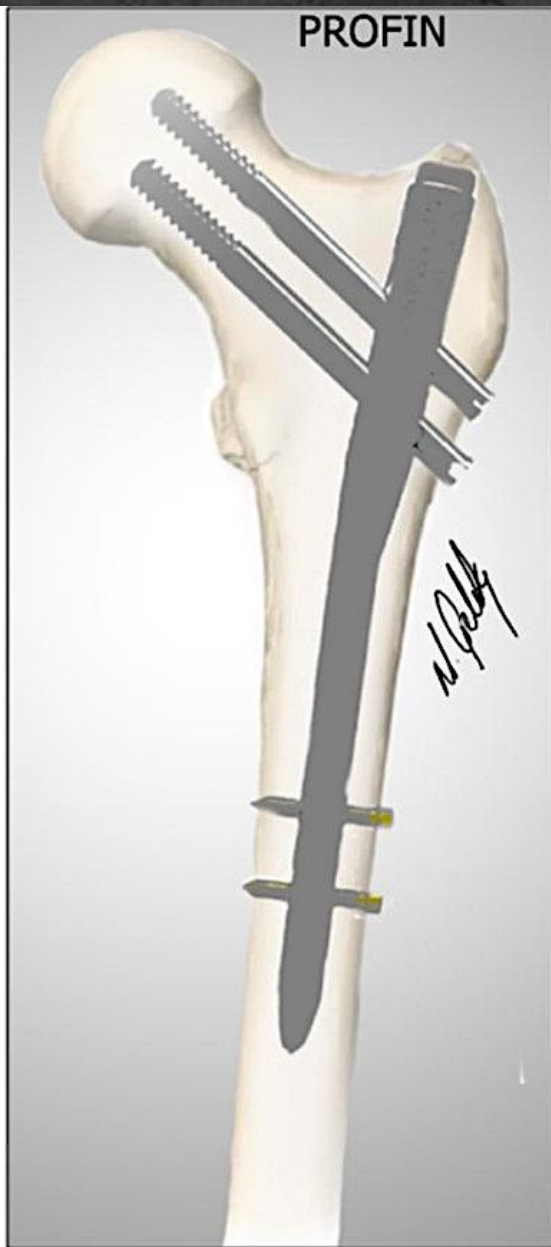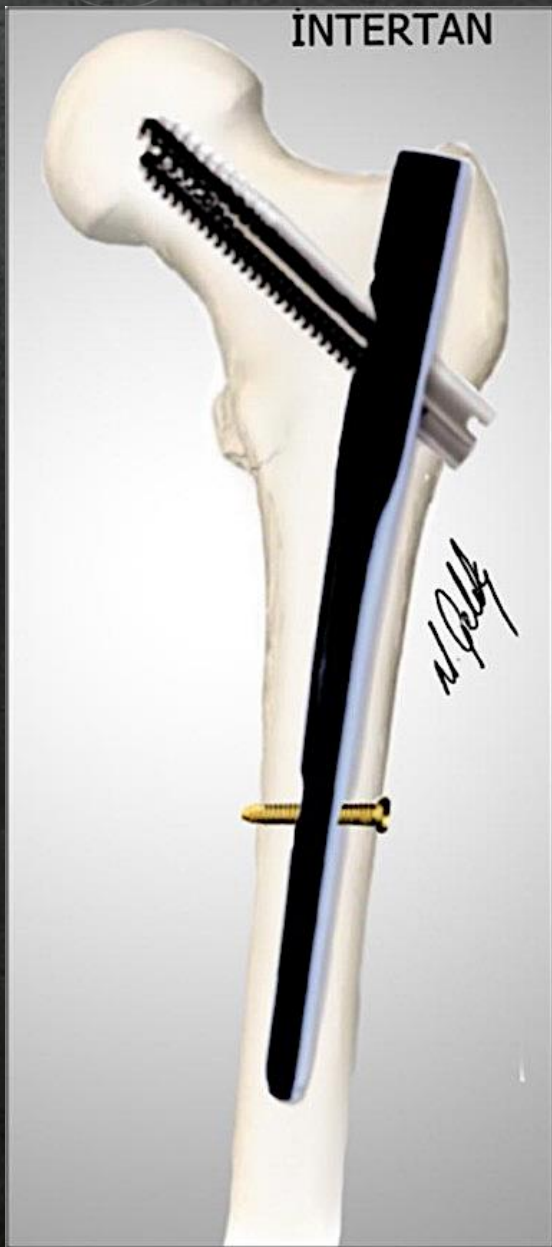Intertrochanteric

DHS



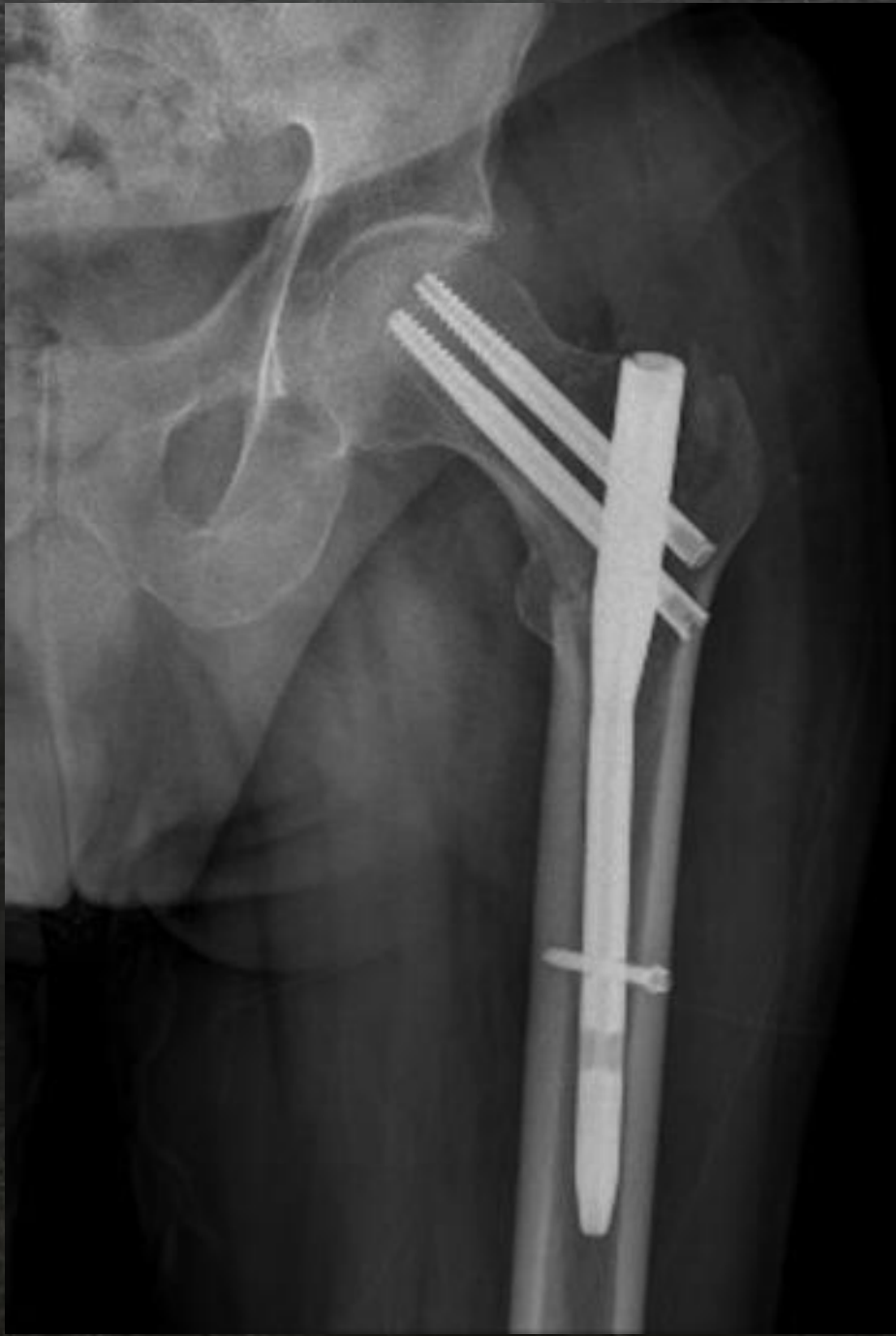Intertrochanteric

PFN



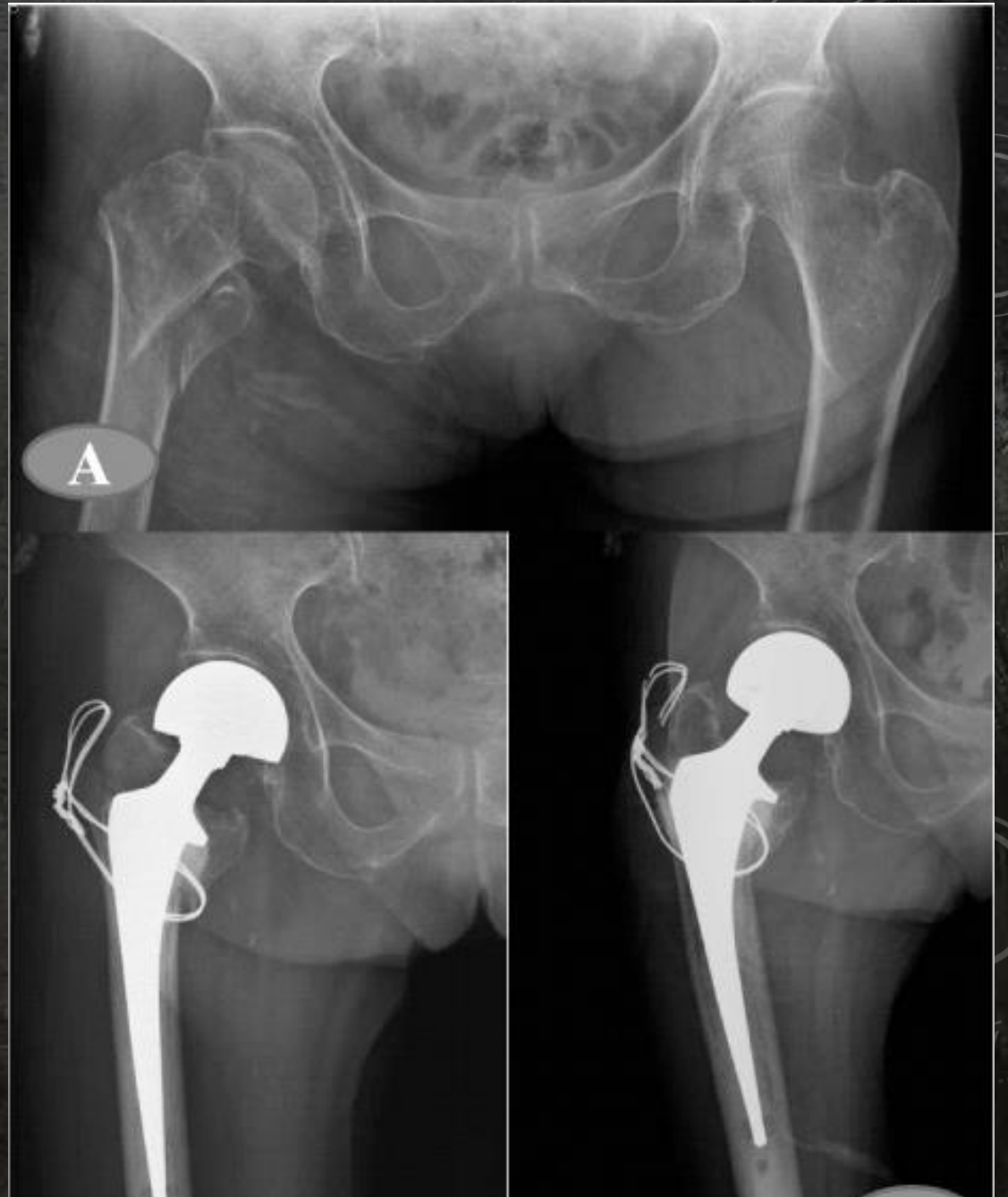Intertrochanteric

PFN



Intertrochanteric

Replacement



Features	Intracapsular Fractures of Neck of Femur	Extracapsular Fractures of Neck of Femur
Age	Elderly, after fifth decade	After sixth decade
Sex	Female . male	Male . female
Nature of injury	Trivial	Significant
Ability to walk	Usually not able to walk, but may walk in cases of impacted fracture	Walking is not possible
Pain	Mild and appreciated in the groin	Severe pain, and appreciated at the greater trochanter
Swelling	Nil	Severe
Ecchymosi	Nil	Present over the greater trochanter

Swelling	Nil	Severe
Ecchymosis	Nil	Present over the greater trochanter
Tenderness	In the Scarpa's triangle	On the greater trochanter
Deformity	Less than 45° external rotation deformity	More than 45° external rotation deformity
Shortening	Less than 2.5 cm	More than 2.5 cm
Treatment	Always operative (internal fixation/replacement)	Can be managed in traction
Complications	Nonunion and AVN	Malunion

Class Test & Attendance



**Thank
You**